

Minimally Invasive Dentistry Presentation

Indian Country Oral Health ECHO

Mikkell Bowens, DMD
Confederated Tribes of Grand Ronde

Background information

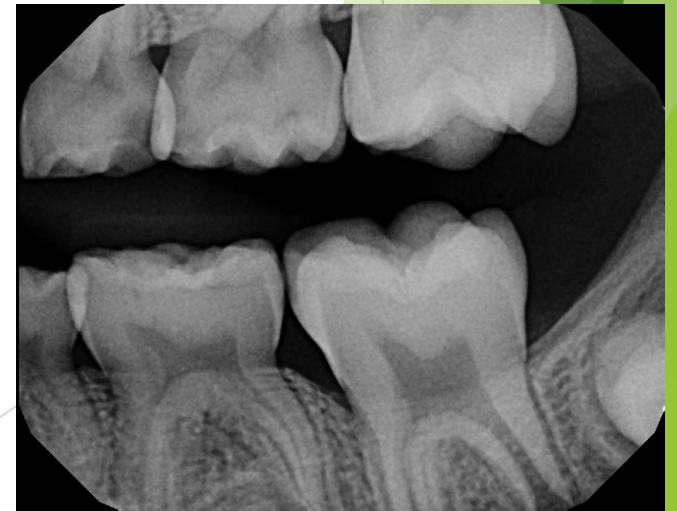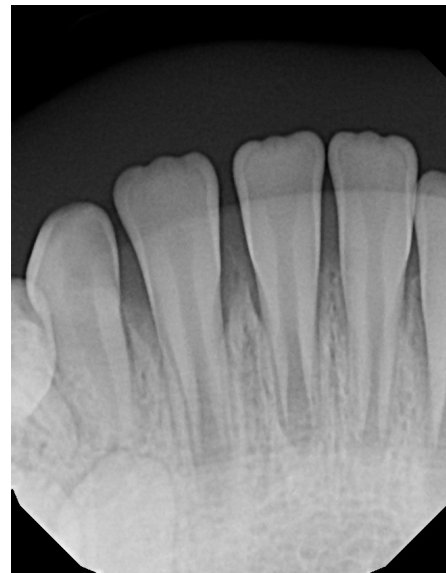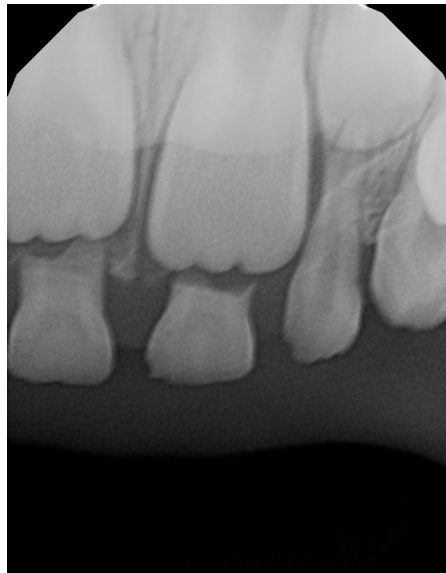
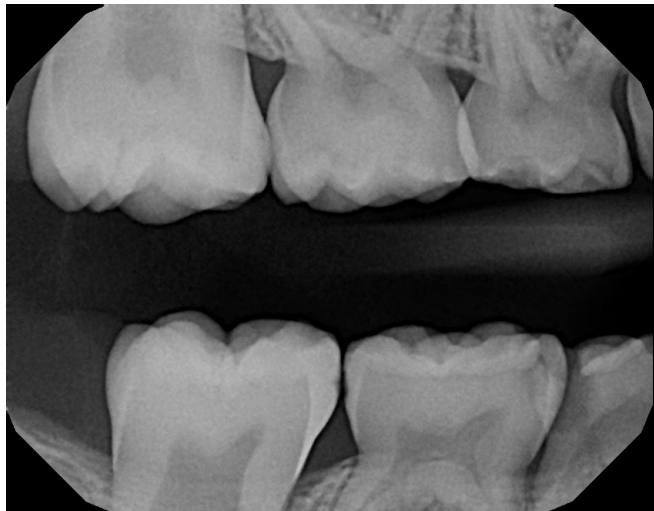
- ▶ **Demographics:**
 - ▶ 18 years old
 - ▶ Male
 - ▶ Current home schooled high school student
 - ▶ Grand Ronde Tribal Member
- ▶ **Social:**
 - ▶ Recently received his Learner's Permit to drive
 - ▶ Likes to play basketball
- ▶ **Medical: Allergy to Augmentin**

Dental History

- ▶ Dental:

- ▶ 2011:

- ▶ Exam completed at 6 years old
 - ▶ Multiple caries and lots of plaque
 - ▶ OHI was provided to patient mother and the notes state the “mother did not seem terribly concerned about many caries”
 - ▶ Prescription provided for fluoride tablets

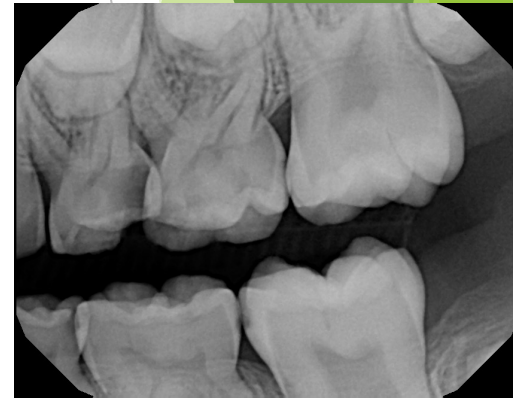
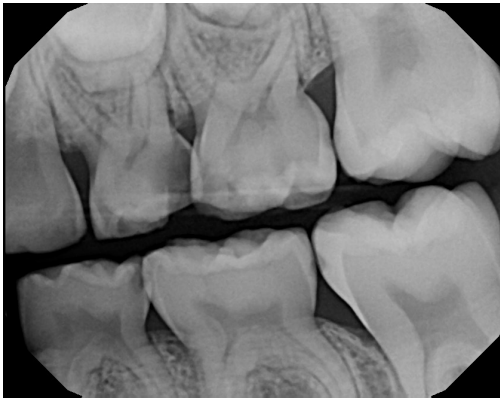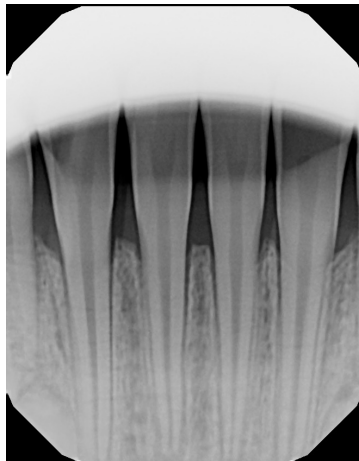
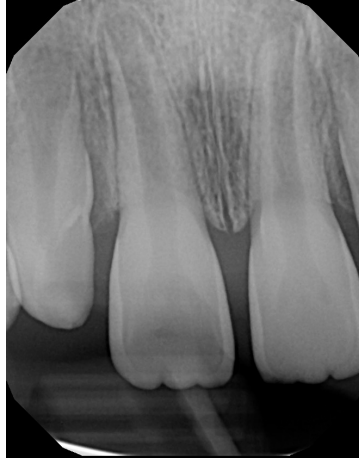
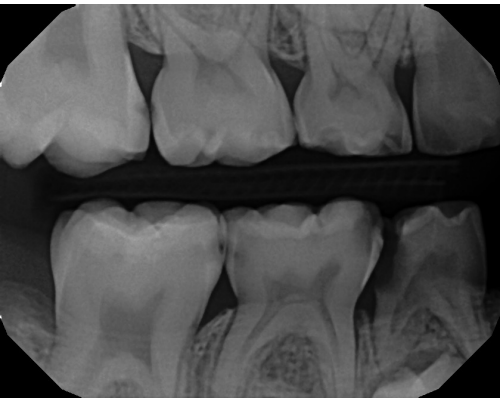
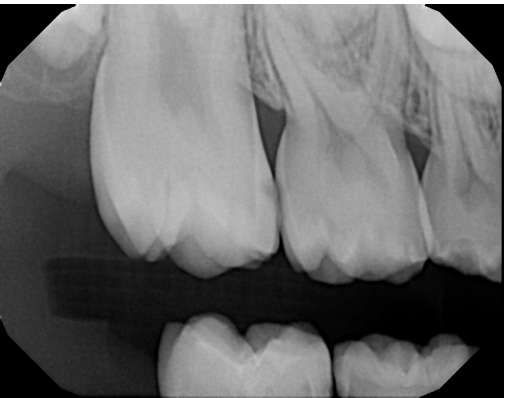


▶ 2012 - 6 months later:

- ▶ New exam completed where Nutrition counsel and OHI were provided as patient stated he drinks a lot of pop
- ▶ Multiple broken appointments following this exam

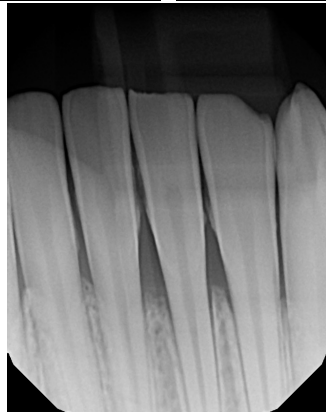
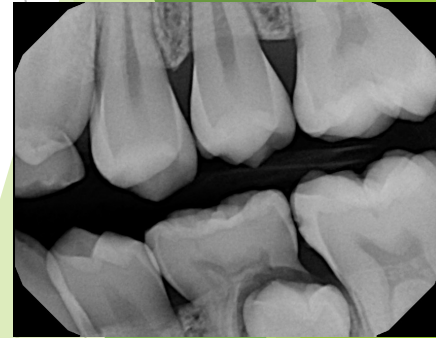
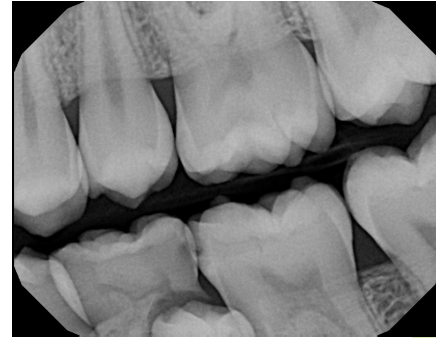
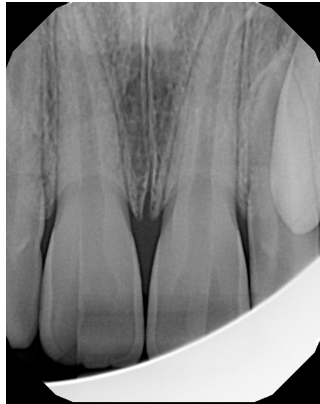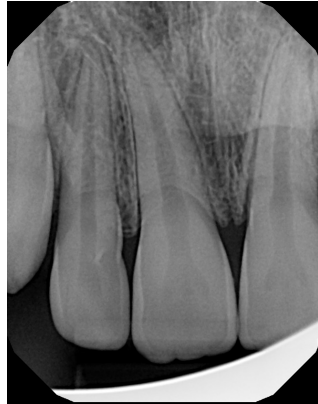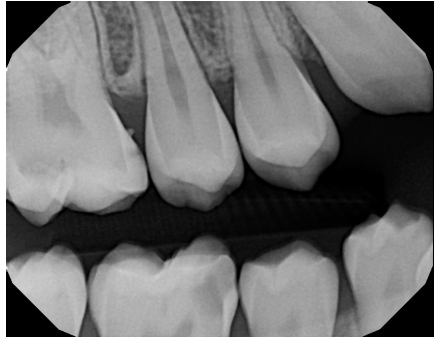
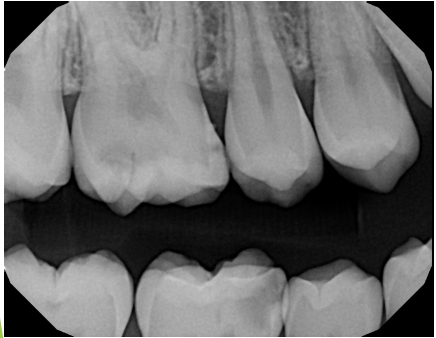
▶ 2012 - 4 months later:

- ▶ Another broken appointment and patient's dad stated they were trying to find a dentist closer to their home and that the patient is in pain



► 2016 (4 years later) - 10 years old:

- Exam completed
- Full mouth debridement completed
- Nutrition counsel provided to patient's grandma discussing the need to decrease apple juice consumption
- Restorative treatment began on large lesions and included a direct pulp cap on #3 and selective caries removal on #30 to avoid a pulp exposure



2021 (5 years later) - 17 years old

- ▶ Comprehensive Exam:

- ▶ Oral cancer screening: EO: WNL IO: WNL
- ▶ Pt admits to not brushing
- ▶ Gingiva: Moderate gingivitis

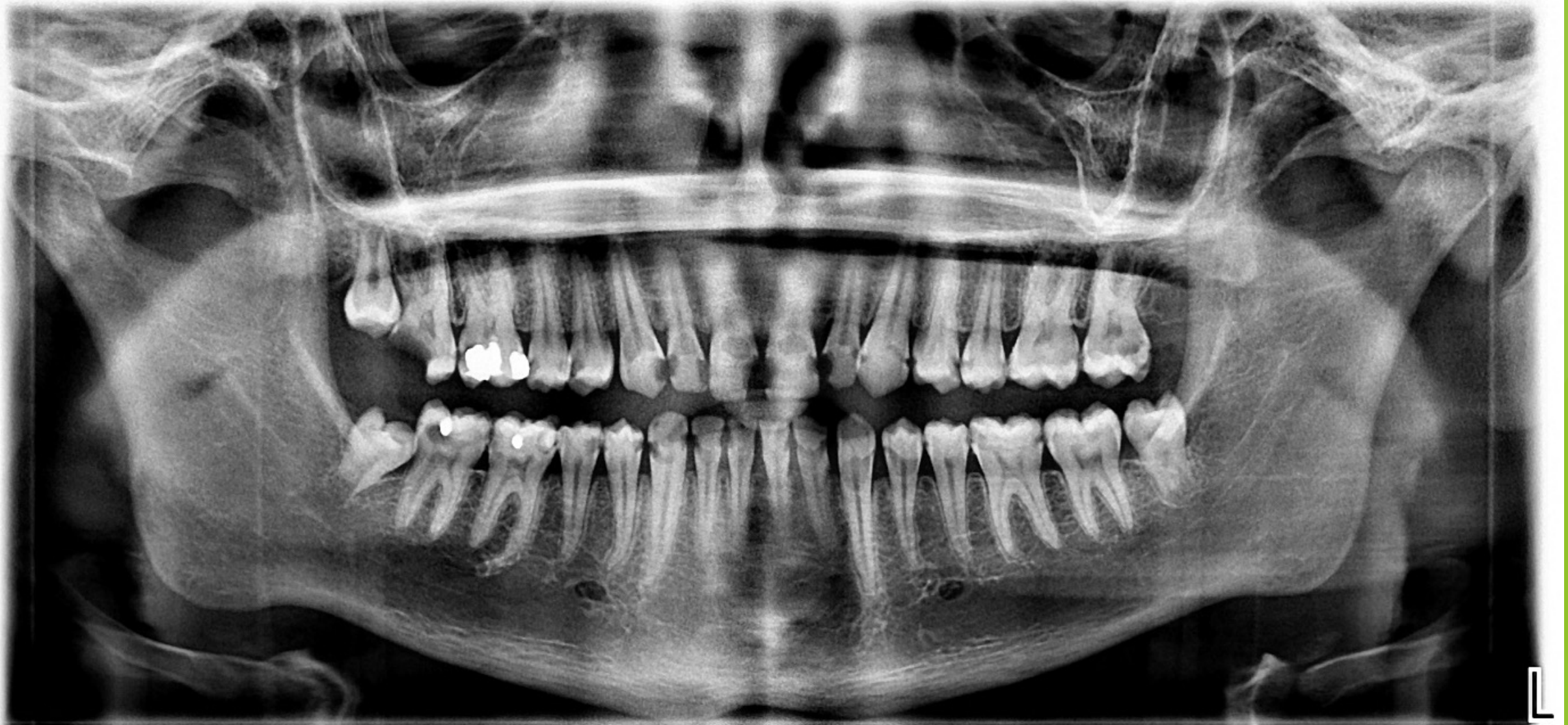- ▶ Chief Complaint:

- ▶ Generalized sensitivity
- ▶ Pain in the front teeth

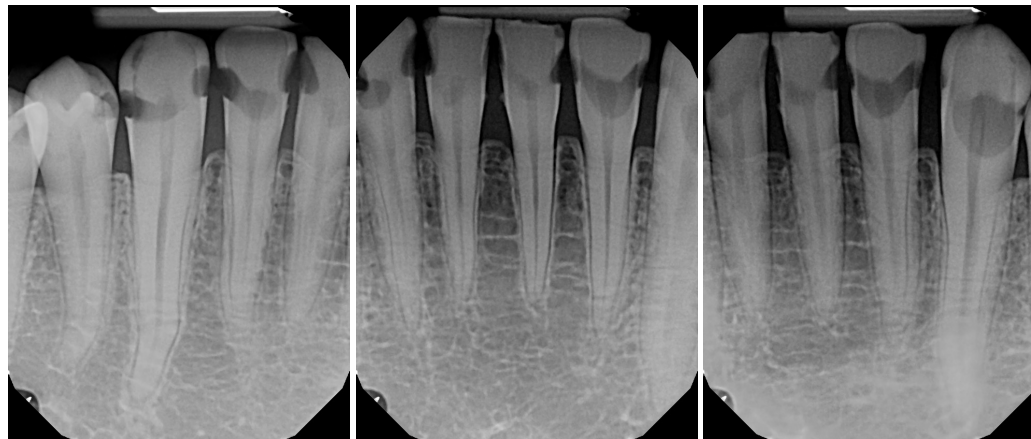
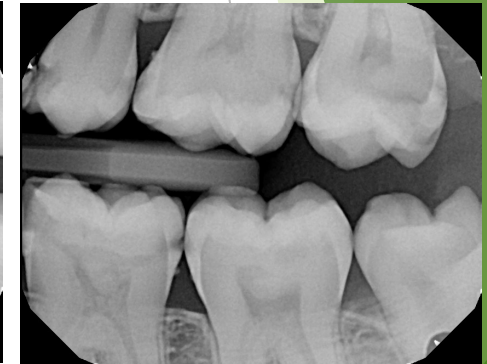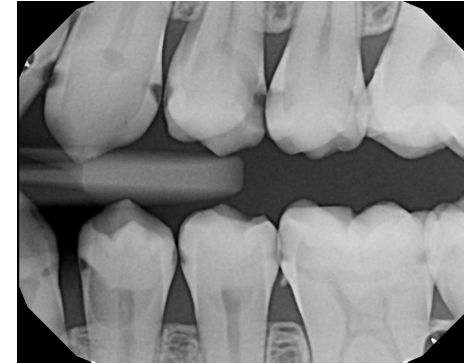
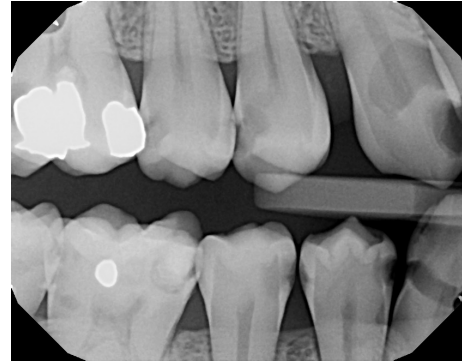
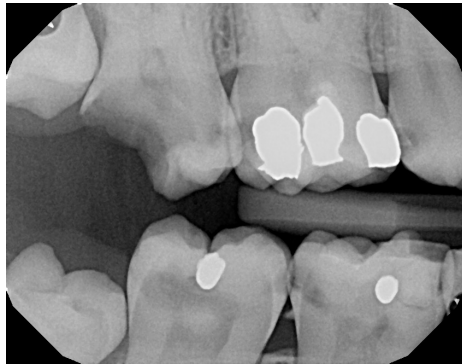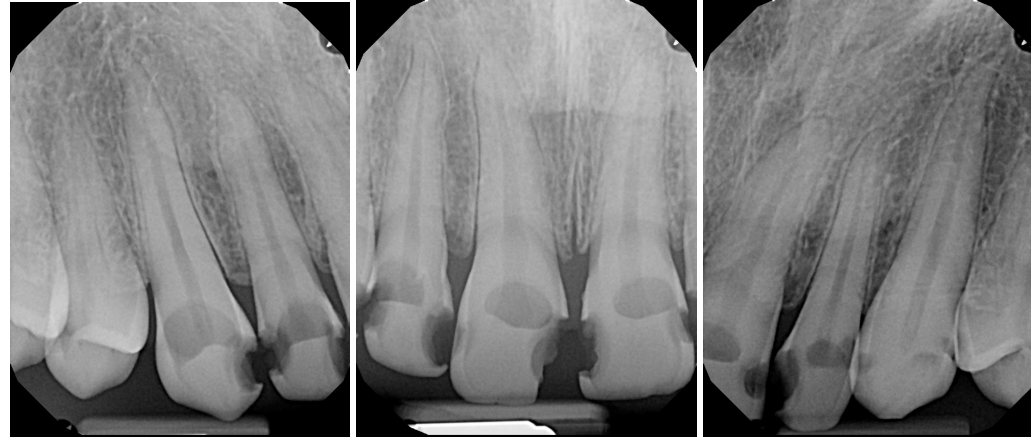
- ▶ Side note:

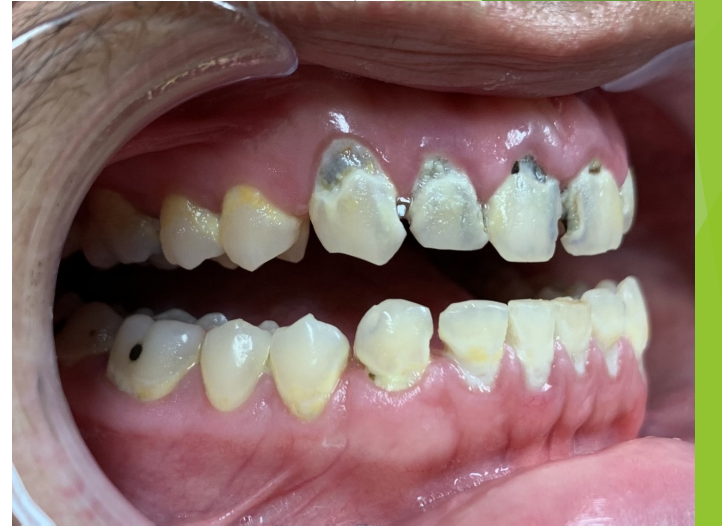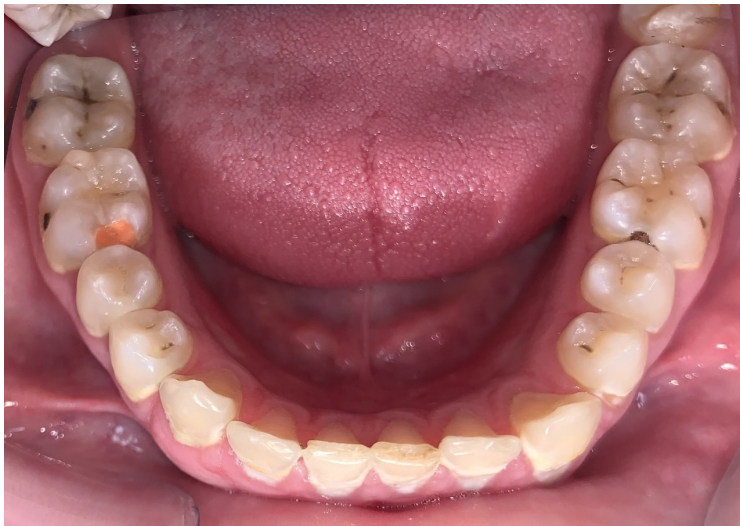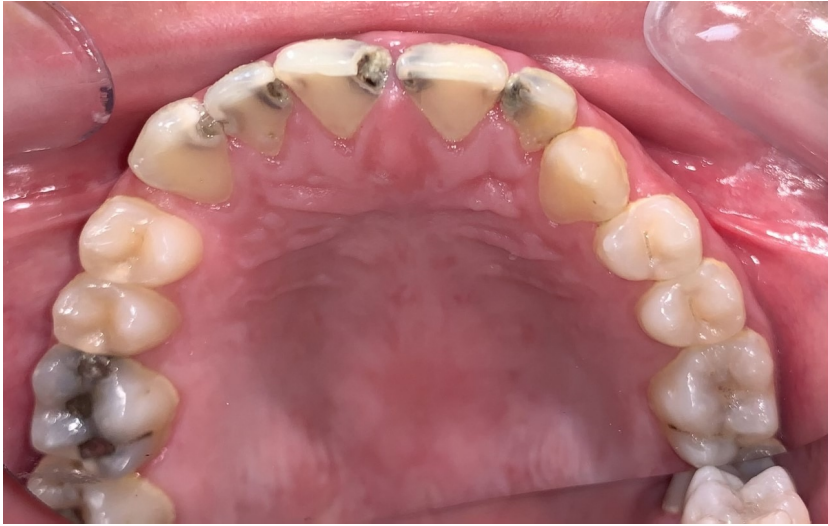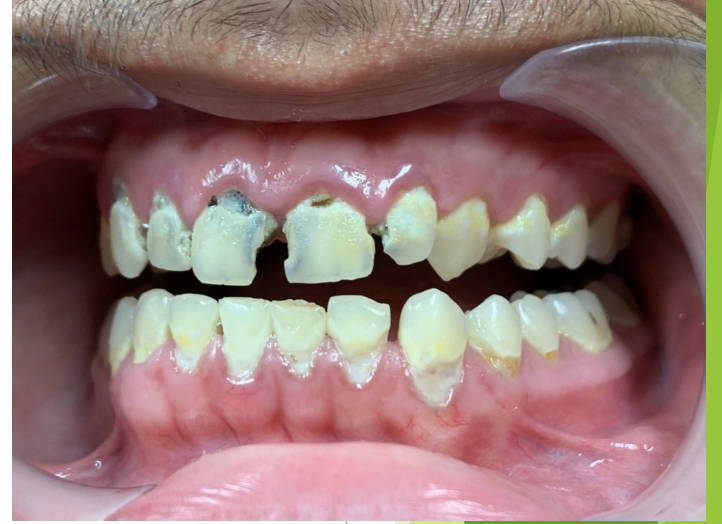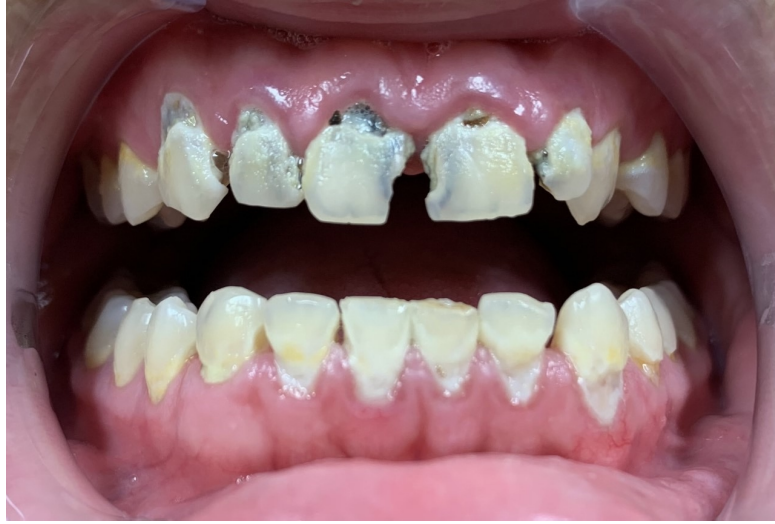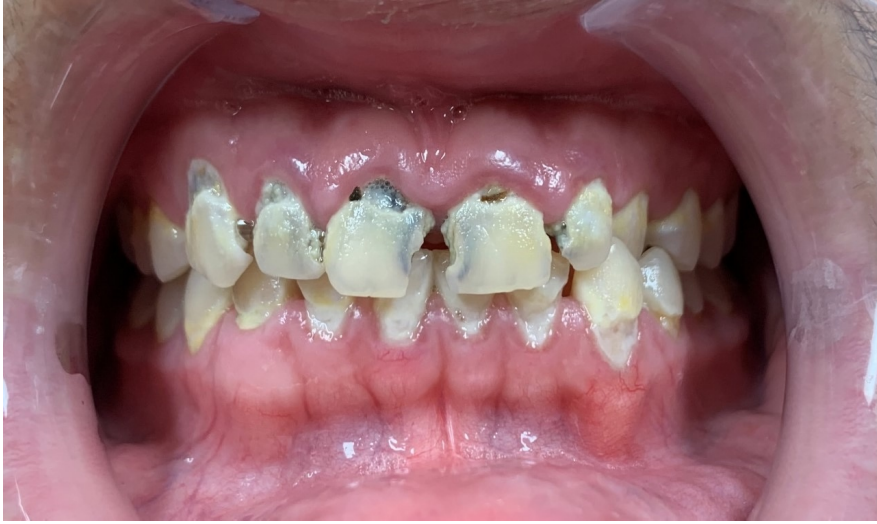- ▶ Patient's mother has severe dental anxiety (barrier to care for patient?)

Panoramic



- ▶ Rampant caries, Heavy plaque
- ▶ #2 and #15 Non-restorable
- ▶ SDF treatments recommended to arrest caries disease progression before definitive treatment recommendations will be provided
- ▶ OHI and nutrition counseling provided
- ▶ SDF applied
- ▶ Provided Preident 5000 toothpaste





▶ SDF and fluoride varnish applied:

▶ 8/26/2021 - Comprehensive exam

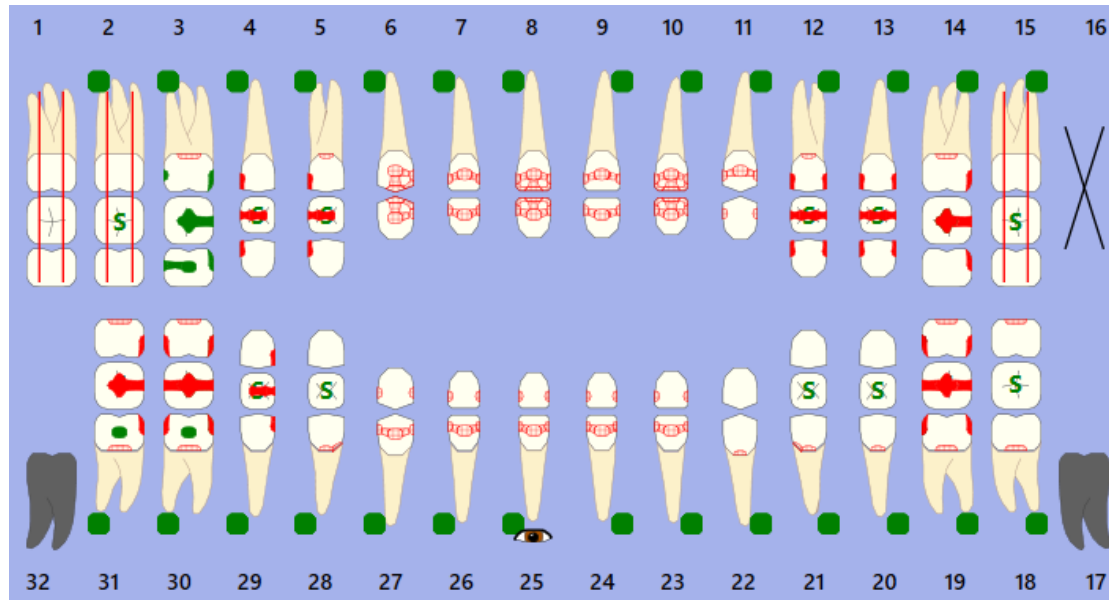▶ 9/1/2021 - Patient states sensitivity is getting better and he has been brushing better.

▶ SDF is arresting caries and teeth are noticeably darker in the carious lesion areas

▶ 9/7/2021 - “My teeth aren’t so sensitive anymore.”

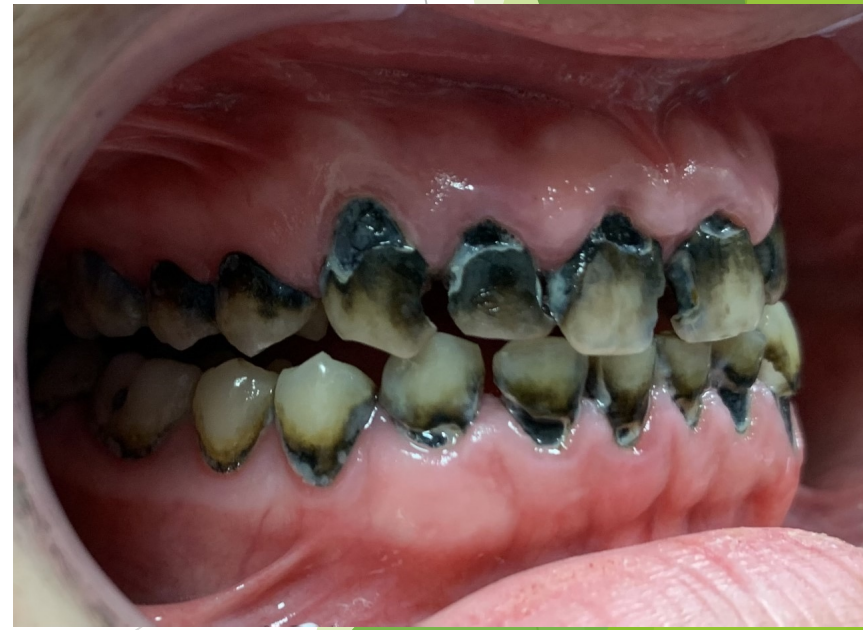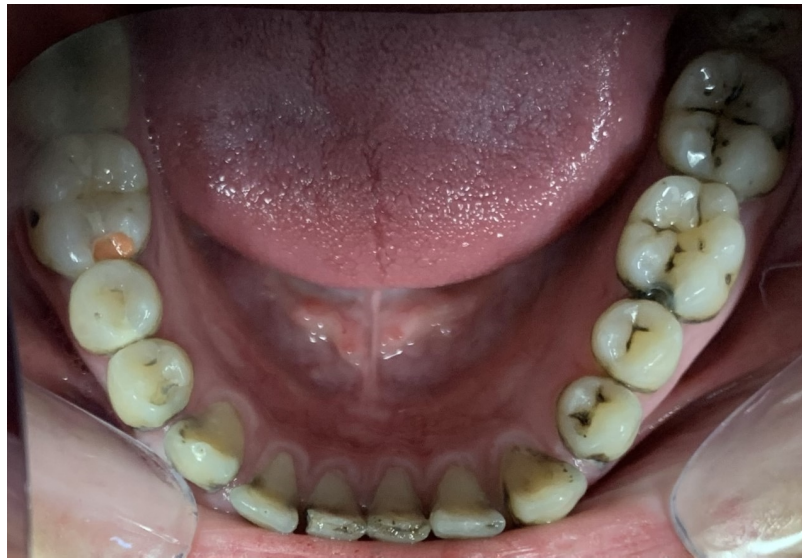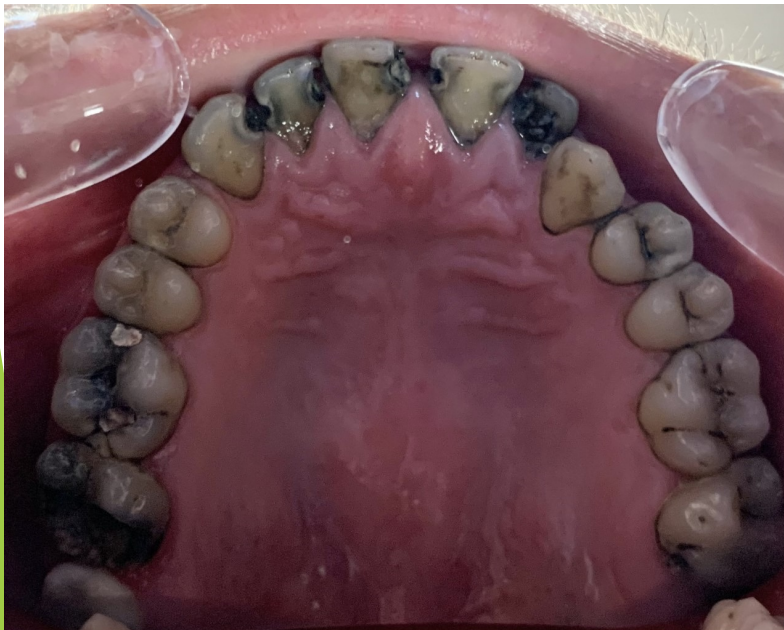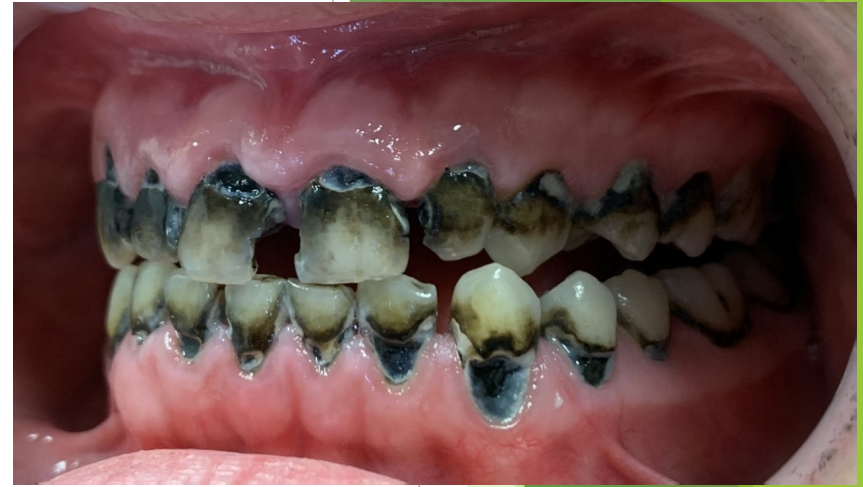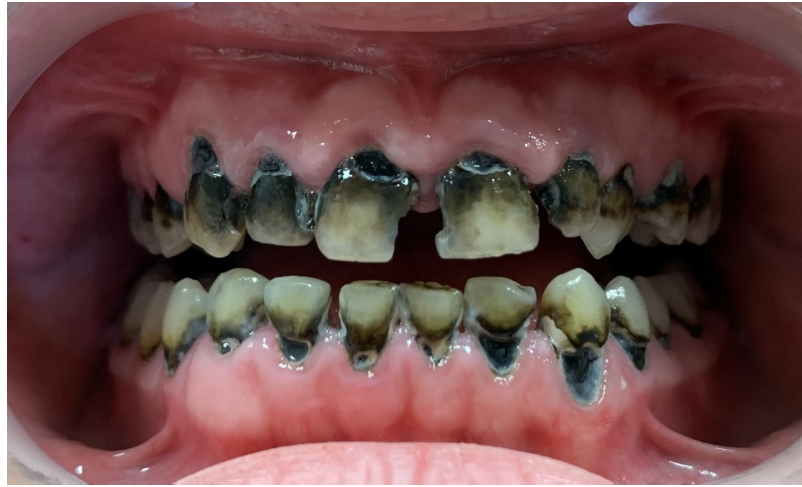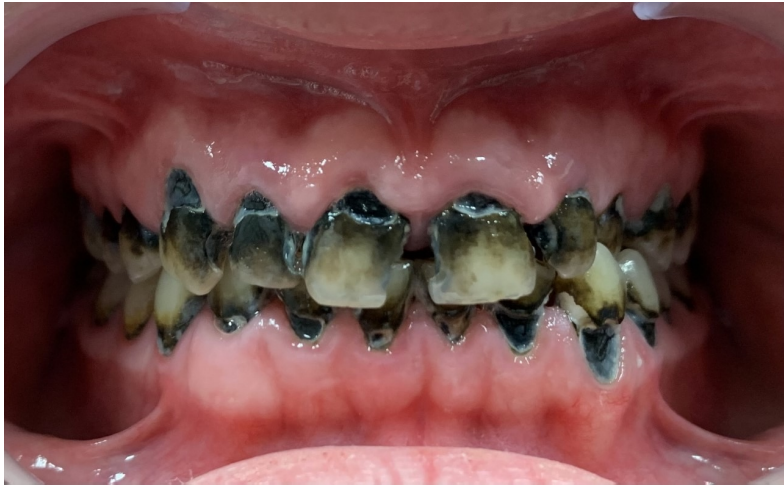▶ Less plaque today than prior visits

▶ 9/29/2021 - Dentition re-evaluated for Glass Ionomer and/or Amalgam restorations



4/28/2022 - 7 months later

- ▶ Presents to the clinic for a limited exam after missing appointment and never rescheduling
- ▶ Chief Complaint:
 - ▶ “I do not like the look of the black teeth.”
- ▶ Re-evaluation of dentition completed:
 - ▶ Caries appears to be arrested
 - ▶ Teeth are blackened and feel hardened
 - ▶ Reapplied SDF, applied Iodine, & fluoride varnish
 - ▶ Provided Prevident 5000 toothpaste again (siblings squirted out the toothpaste and wasted it)



****White is fluoride varnish (not plaque)**