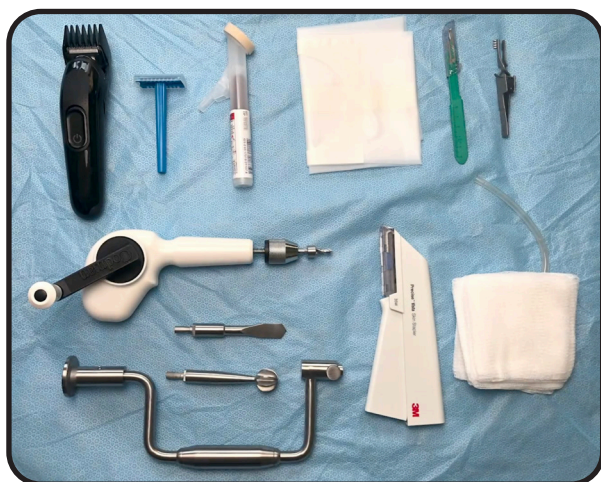



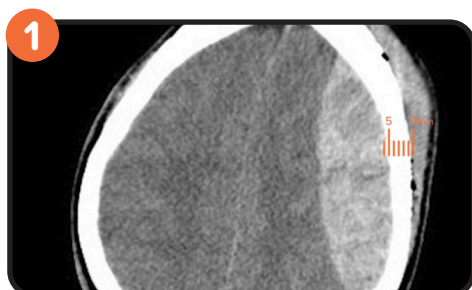
CRANIAL BURR HOLE

Download more *Smart Cards*
at www.emrap.org



Equipment

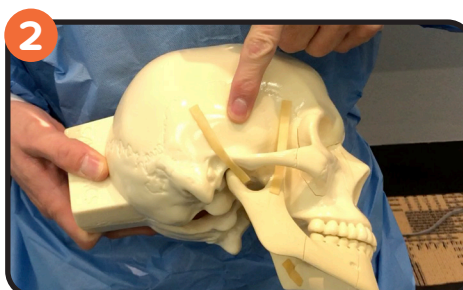
- Hair clippers or razor
- Skin disinfectant
- Drape
- Scalpel
- Self-retaining scalp retractor
- Cranial drill (hand drill and Hudson-brace shown)
- Skin stapler
- Drain
- Gauze



1

Review CT

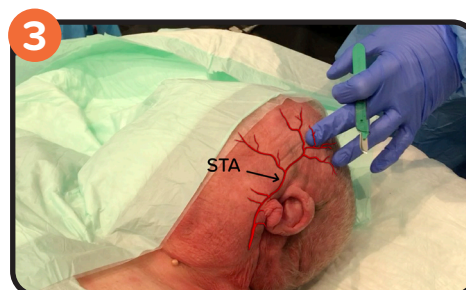Use CT to identify the site. Measure the skull to determine depth to drill.



2

Landmarks

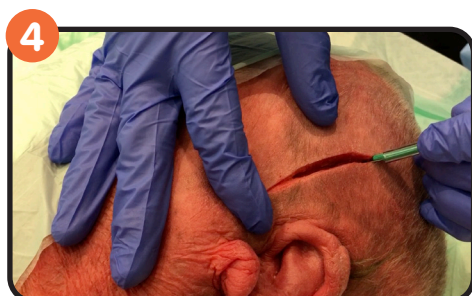If no CT is available: 2 cm superior, 2 cm anterior to tragus, ipsilateral to blown pupil (temporal site). Shave the hair, prep and drape.



3

Reduce scalp bleeding

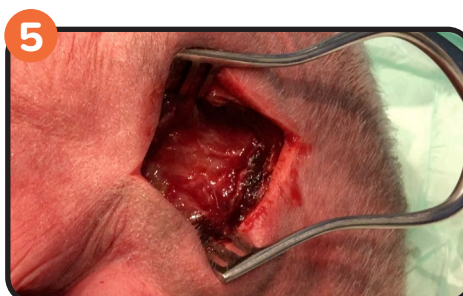Inject lidocaine with epinephrine. Palpate the superficial temporal artery (STA) and remain anterior to it.



4

Skin incision

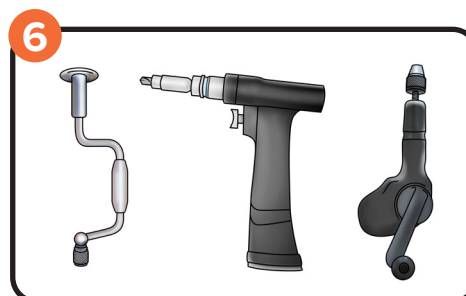
Make a 3-5 cm vertical incision down to bone. Control scalp bleeding; the frontal branch of the STA is often transected.



5

Insert the retractor

Insert the self-retaining scalp retractor to expose periosteum.



6

Trephination

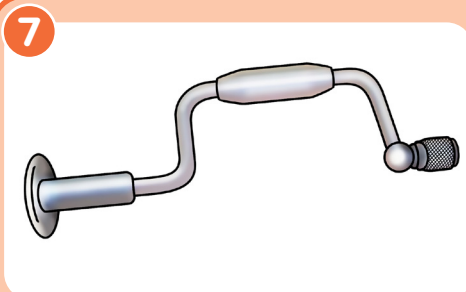
Technique varies with equipment. Have an assistant stabilize the head.

This is for reference purposes only. Consent to photograph was obtained from the patient or family. EM:RAP and the authors assume no liability for use of the techniques described. Local practice, current guidelines, and clinician experience should determine the exact procedural process in any individual patient.

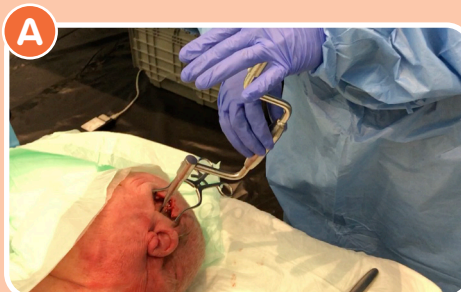


CRANIAL BURR HOLE

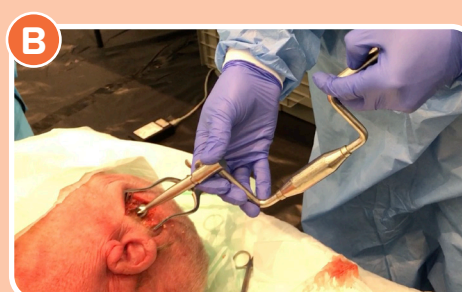
Download more *Smart Cards*
at www.emrap.org



7
Using a Hudson-Brace

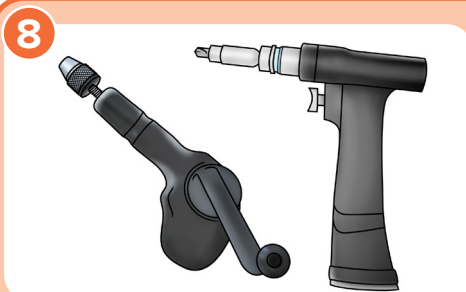


A
Drilling with the perforator bit
Use the perforator bit to drill through the outer table, felt as a smooth drilling motion.

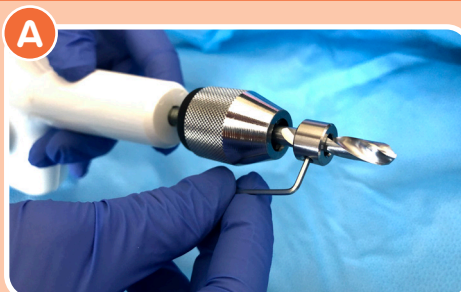

B
Drilling with the conical burr
When the drilling motion becomes jagged, switch to the conical burr to trephinate the inner table of the skull.

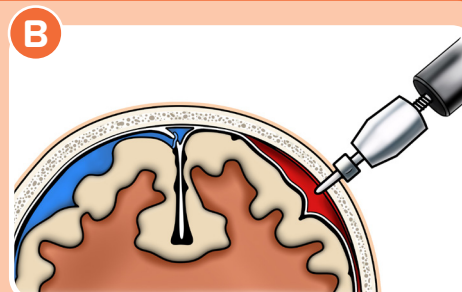
Note: the non-rotating hand should provide counter-torque and resist forward motion of the drill.



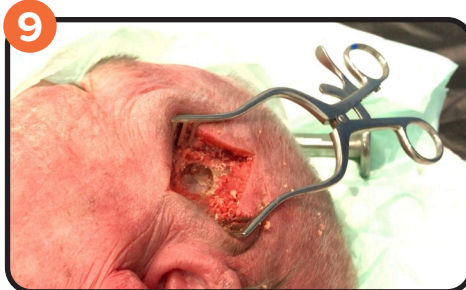
8
Using a hand or electric drill



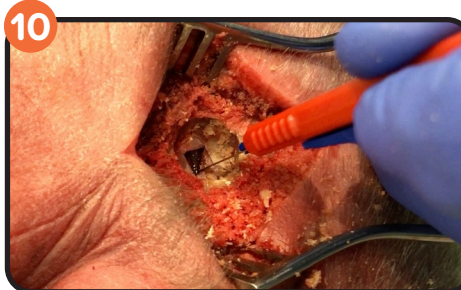
A
Set the Stopper
Set the stopper based on the CT to prevent drilling too deeply (typically 0.5-2 cm). Use the largest drill bit in the kit.



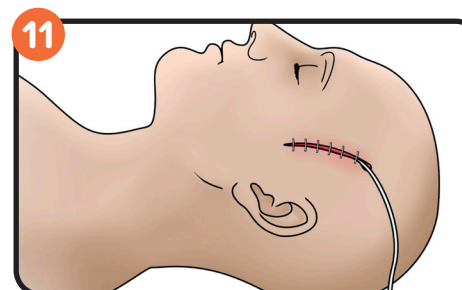
B
Drill through the skull
Drill through the inner table of the skull.



9
Epidural hematoma
Evacuate epidural blood with irrigation and gentle suction.



10
Subdural hemorrhage
For a subdural bleed, make a three-sided (or "X") incision in the dura. Use irrigation but do **NOT** suction.



11
Skin closure
Leave a drain in place as blood will reaccumulate. Close the skin for hemostasis.

Note: Burr holes without CT guidance can be done in the following sequence: ipsilateral temporal, contralateral temporal, ipsilateral frontal, ipsilateral parietal. See video.

This is for reference purposes only. Consent to photograph was obtained from the patient or family. EM:RAP and the authors assume no liability for use of the techniques described. Local practice, current guidelines, and clinician experience should determine the exact procedural process in any individual patient.