Indian Country Oral Health ECHO:
Minimally Invasive Dentistry and Case Presentation

WELCOME!



NORTHWEST PORTLAND AREA
INDIAN HEALTH BOARD
Indian Leadership for Indian Health

Photo of artwork in CTCLUSI tribal

Northwest Portland Area Indian Health Board

Established in 1972, the Northwest Portland Area Indian Health Board (NPAIHB or the Board) is a non-profit tribal advisory organization serving the forty-three federally recognized tribes of Oregon, Washington, and Idaho. Each member tribe appoints a Delegate via tribal resolution and meets quarterly to direct and oversee all activities of NPAIHB.

"Our mission is to eliminate health disparities and improve the quality of life of American Indians and Alaska Natives by supporting Northwest Tribes in their delivery of culturally appropriate, high-quality healthcare."

NORTHWEST PORTLAND AREA
INDIAN HEALTH BOARD
Indian Leadership for Indian Health

Indian Country Oral Health ECHO:
Minimally Invasive Dentistry and Case Presentation

Photo of artwork in Nez Perce National Historical Park Visitor Center

DISCLAIMER:
We have no financial disclosures or conflicts of interest with the information in this presentation.

NORTHWEST PORTLAND AREA INDIAN HEALTH BOARD
Indian Leadership for Indian Health

Indian Country Oral Health ECHO:

Faculty:

Sean Kelly
DDS, MSHS
NTDSC-
Clinical Consultant

Martin Lieberman
DDS, MA
VP, Graduate Dental Education,
NYU-Langone
Arcora Foundation-
Consultant

Miranda Davis
DDS, MPH
TCHPP-
Dental Health Aide Program Director
NTDSC-
Prevention Consultant

Pam Ready (Puyallup)
RDH, MSDH
TCHPP-
DHA Education Manager

Ticey Mason (Siletz)
MA
NTDSC-
Project Director

NORTHWEST PORTLAND AREA
INDIAN HEALTH BOARD
Indian Leadership for Indian Health

Objectives:

Upon completion of this course, participants will be able to:

1. **Build minimally invasive dentistry skills.**

2. **Recognize risk factors and apply preventive measures to reduce the occurrence of oral health disease.**

3. **Learn techniques on how to treat patients with holistic and culturally appropriate care.**

NORTHWEST PORTLAND AREA
INDIAN HEALTH BOARD
Indian Leadership for Indian Health

Outline:

1. Case Presentation

2. Didactic Presentation
   -Hall Crowns

3. Group Discussion and Q&A

NORTHWEST PORTLAND AREA
INDIAN HEALTH BOARD
Indian Leadership for Indian Health

“The evidence-base for survival of restorations clearly indicates that restoring teeth is a temporary palliative measure that is doomed to fail if the disease that caused the condition is not addressed properly.”

https://pubmed.ncbi.nlm.nih.gov/15646587/

NORTHWEST PORTLAND AREA INDIAN HEALTH BOARD
Indian Leadership for Indian Health

PubMed.gov

Search

Advanced

User Guide

Save | Email | Send to | Display options

Oral Health Prev Dent. 2004;2 Suppl 1:287-92.

What is minimally invasive dentistry?

Dan Ericson [1]

Affiliations + expand

PMID: 15646587

Abstract

Minimally Invasive Dentistry is the application of "a systematic respect for the original tissue." This implies that the dental profession recognizes that an artifact is of less biological value than the original healthy tissue. Minimally invasive dentistry is a concept that can embrace all aspects of the profession. The common delineator is tissue preservation, preferably by preventing disease from occurring and intercepting its progress, but also removing and replacing with as little tissue loss as possible. It does not suggest that we make small fillings to restore incipient lesions or surgically remove impacted third molars without symptoms as routine procedures. The introduction of predictable adhesive technologies has led to a giant leap in interest in minimally invasive dentistry. The concept bridges the traditional gap between prevention and surgical procedures, which is just what dentistry needs today. The evidence-base for survival of restorations clearly indicates that restoring teeth is a temporary palliative measure that is doomed to fail if the disease that caused the condition is not addressed properly. Today, the means, motives and opportunities for minimally invasive dentistry are at hand, but incentives are definitely lacking. Patients and third parties seem to be convinced that the only things that count are replacements. Namely, they are prepared to pay for a filling but not for a procedure that can help avoid having one.

ACTIONS

Cite

Favorites

SHARE

PAGE NAVIGATION

- Title & authors
- Abstract
- Similar articles
- Cited by
- MeSH terms
- LinkOut - more resources

Indian Country Oral Health ECHO:

Minimally Invasive Dentistry and Case Presentation

Today's Clinical Faculty:

Sean Kelly, DDS, MSHS
NTDSC-
Clinical Consultant

Martin Lieberman, DDS, MA
VP, Graduate Dental Education, NYU-Langone
Arcora Foundation-
Consultant

Miranda Davis, DDS, MPH
TCHPP-
Dental Health Aide Program Director
NTDSC-
Prevention Consultant

NORTHWEST PORTLAND AREA
INDIAN HEALTH BOARD
Indian Leadership for Indian Health

Case Presentation

NORTHWEST PORTLAND AREA
INDIAN HEALTH BOARD
Indian Leadership for Indian Health

MID in Action

Indian Country Oral Health ECHO

Provided by:

Taylor Wilkens, DDS

Dental Director

Marimn Dental Clinic

Coeur d'Alene Tribe

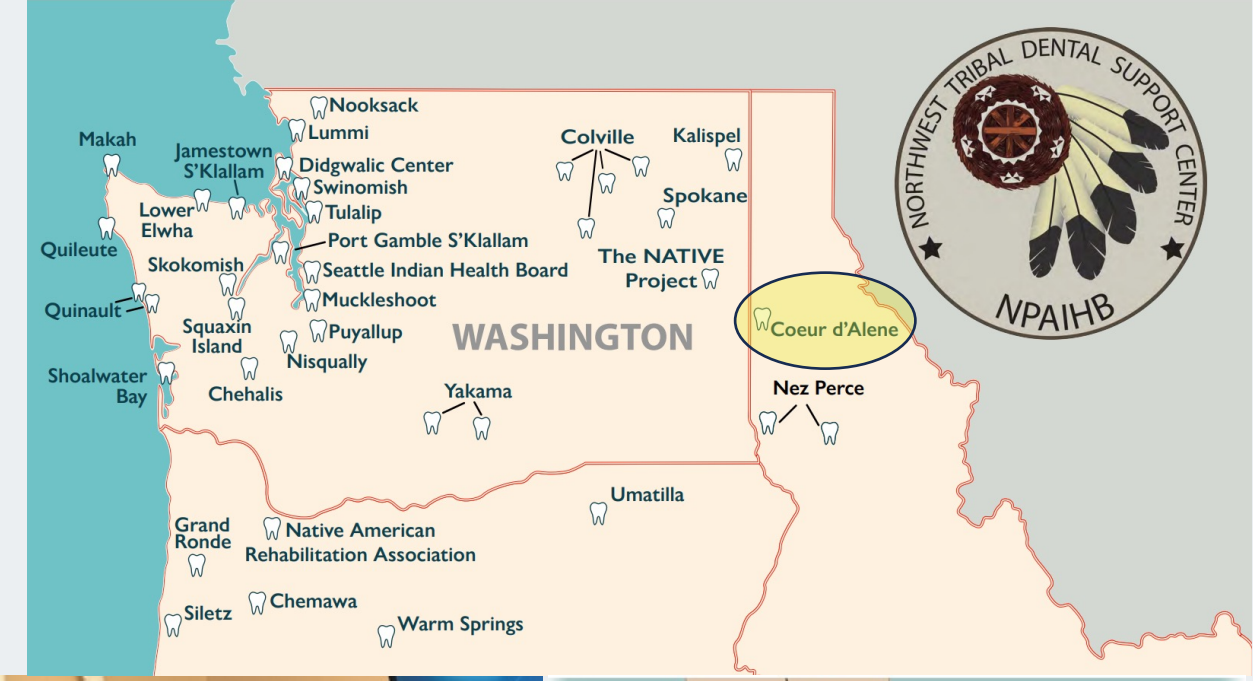

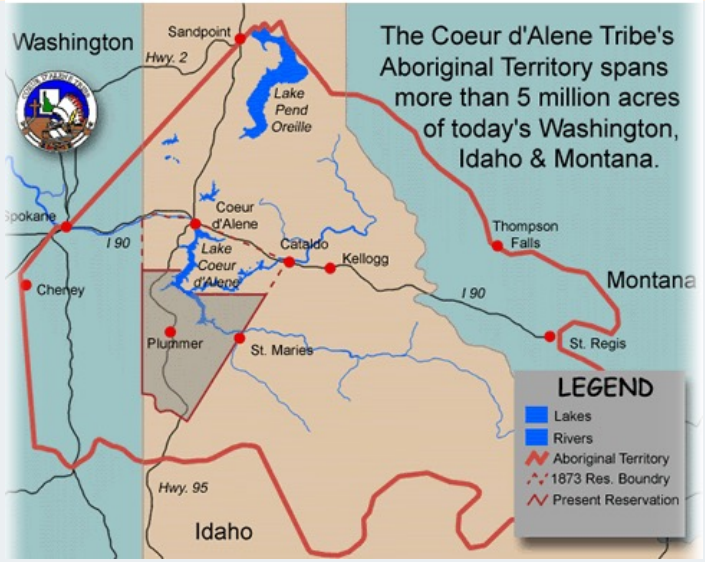

Above Image from:
https://www.cdatribe-nsn.gov/our-tribe/tribal-lands/

NORTHWEST PORTLAND AREA INDIAN HEALTH BOARD

Indian Leadership for Indian Health

Hall Crown Case Presentation

Taylor Wilkens

MARIMNHEALTH
COEUR D'ALENE TRIBE

Case #1

- 5 y.o. female presents for first dental exam and cleaning. Parents have noticed a cavity.
- No health history concerns.
- Oral Hygiene: slight plaque
- Discussed treatment options with parents (MID, conventional restorative or referral).
- Parents decided to proceed with MID and we discussed the guarded prognosis of #J and #T.

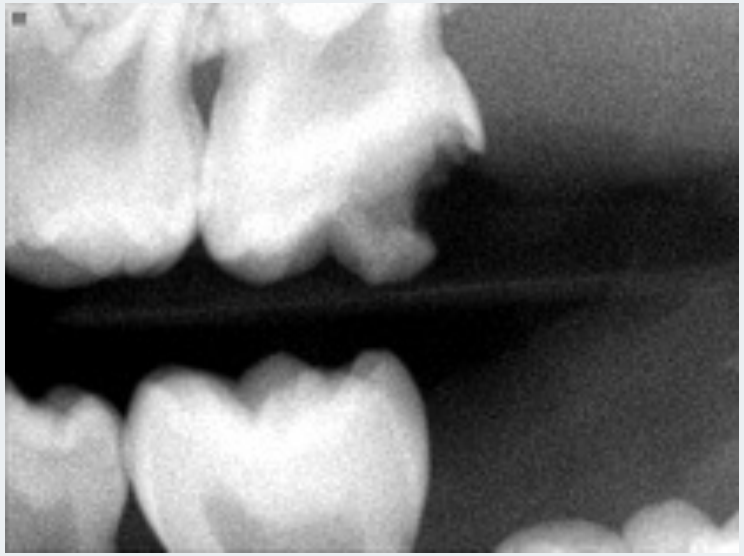

NORTHWEST PORTLAND AREA
INDIAN HEALTH BOARD
Indian Leadership for Indian Health

MARIMNHEALTH
COEUR D'ALENE TRIBE

Initial #J/T – 4/19/2019

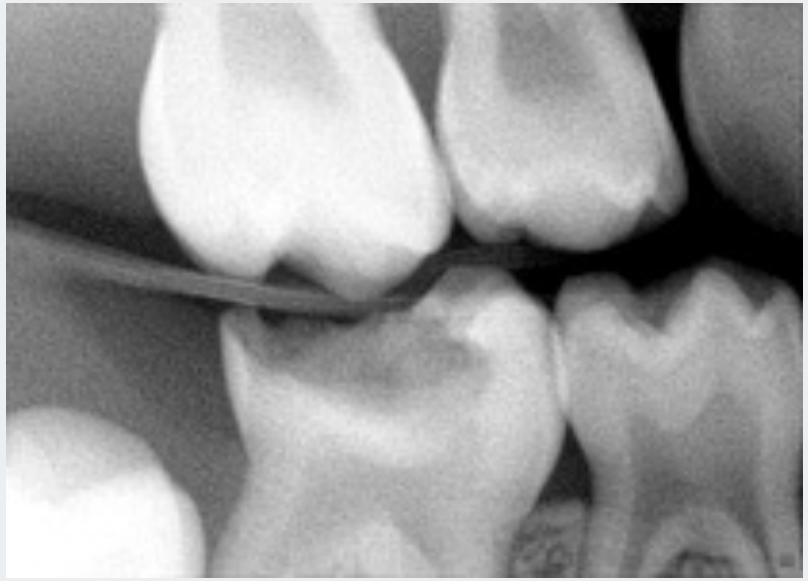

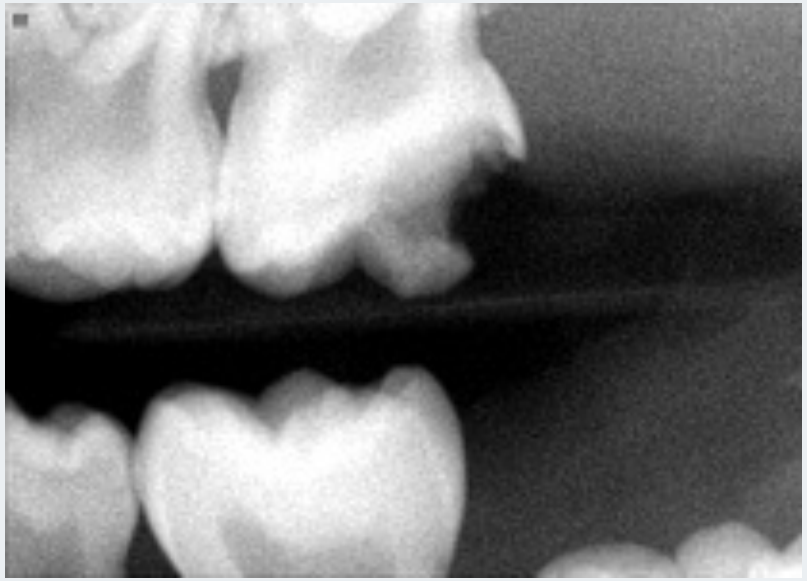

Clinical Findings:

- No history of pain
- No sign of infection
- Furcation bone and tissue WNL
- Pulp possibly involved

Goals Of Treatment:

- Positive experience for the patient.
- Maintain 2nd primary molars as long as possible.

MARIMNHEALTH
COEUR D'ALENE TRIBE

Treatment Day 5/13/2019

- Removed spacers, size 3 Isoform SSC fitted to the teeth.
- Spoon excavation of soft decay and applied SDF.
- Cemented crowns with Fuji 9
- Patient left smiling and laughing!

Postop #J/T

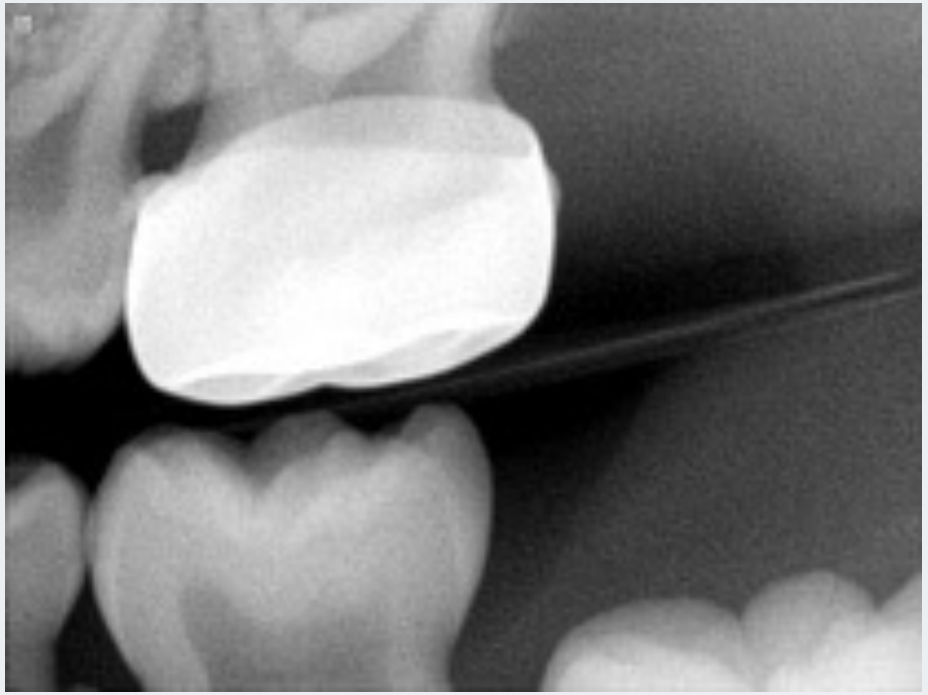

INDIAN HEALTH BOARD
Indian Leadership for Indian Health

MARIMNHEALTH
COEUR D'ALENE TRIBE

November 2020

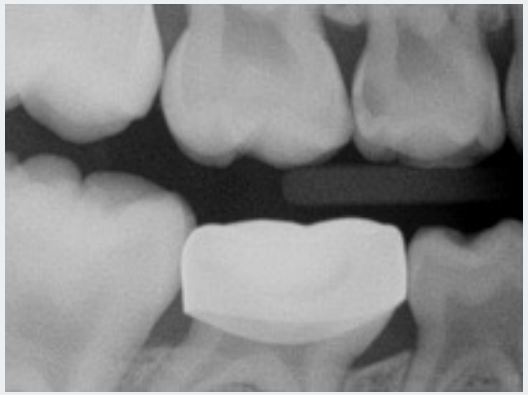

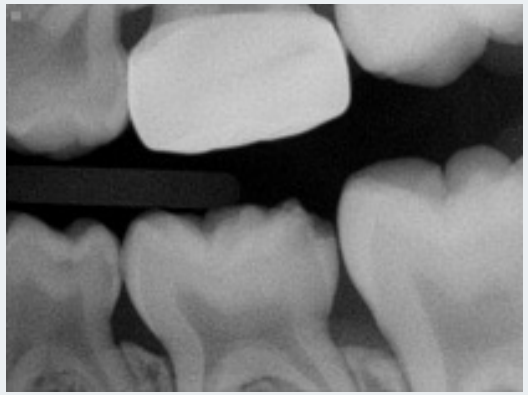

December 2023

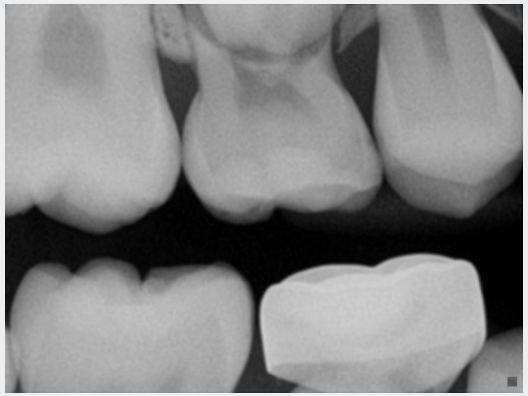

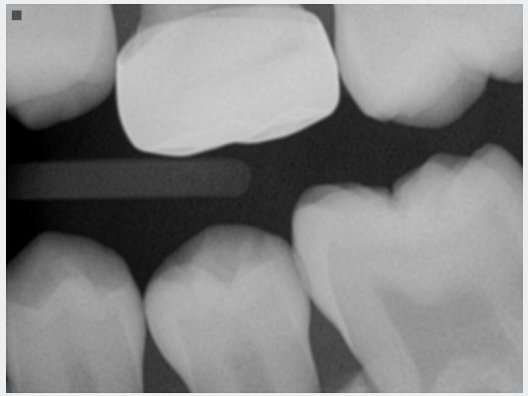

NORTHWEST PORTLAND AREA
INDIAN HEALTH BOARD
Indian Leadership for Indian Health

MARIMNHEALTH
COEUR D'ALENE TRIBE

Success!

Goals of Treatment:

- Positive experience for the patient.
- Maintain 2nd primary molars at least until 1st permanent molars erupt.
- Delay a tooth fairy visit for as long as possible.

NORTHWEST PORTLAND AREA
INDIAN HEALTH BOARD
Indian Leadership for Indian Health

MARIMNHEALTH
COEUR D'ALENE TRIBE

Case #2

- 7.5 y.o. male presents for first dental exam and cleaning. Mom has no concerns other than has noticed cavities.
- Patient followed directions well but seemed shy.
- Discussed treatment options with mom. Mom requests to proceed in the clinic and avoid referral if possible. She did not want to use N_2O.
- No health history concerns.
- Oral Hygiene: Slight plaque

NORTHWES
INDIAN HEA
Indian Leadersh

MARIMNHEALTH
COEUR D'ALENE TRIBE

Clinical findings:

- Posterior decay only.
- Depth of decay in #A/B/K/L/S/T is concerning.
- Patient scheduled to return for Hall Crowns on a training day with an instructor and our staff.

Initial Exam 2/6/2018

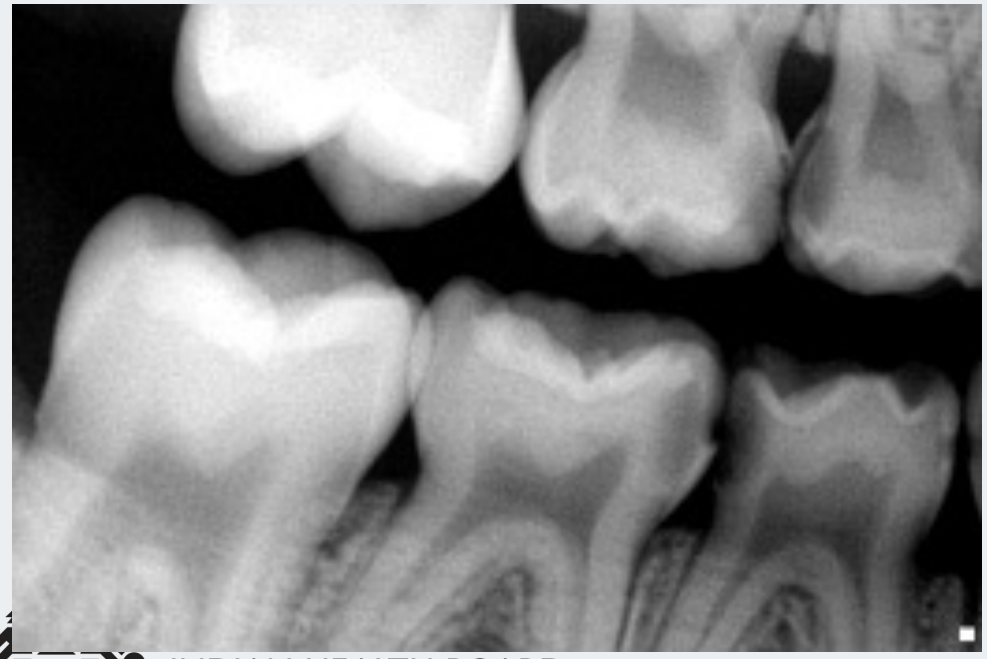

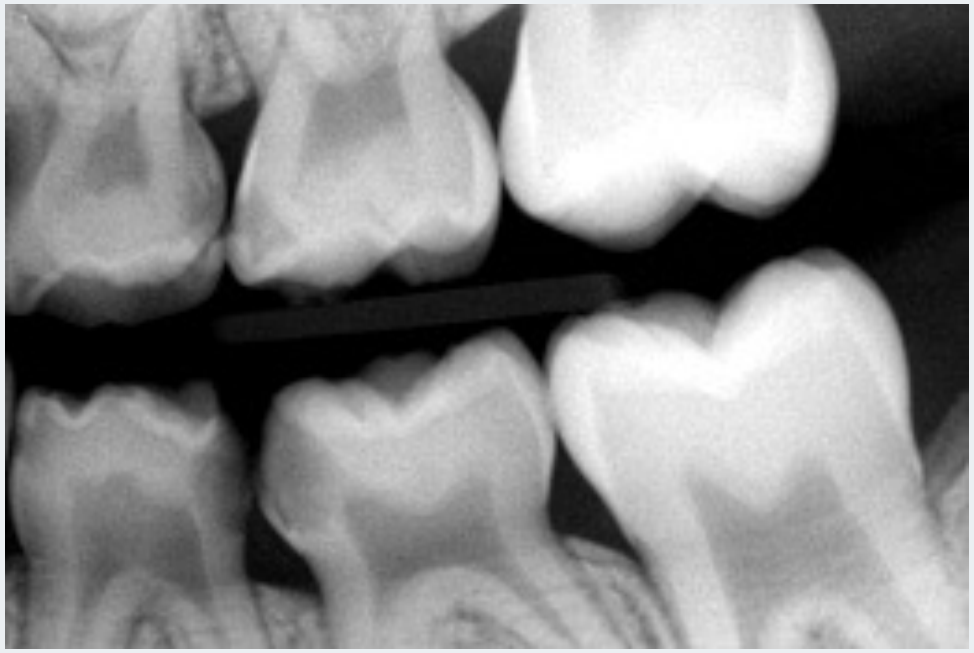

MARIMNHEALTH
COEUR D'ALENE TRIBE

1st Apt: Initial Exam
2nd Apt: SDF all posteriors, sealants on 1st molars, SSCs on #A/K.
3rd Apt: Attempted hall crowns #L/T, SMART fills #L/S/T
4th Apt: Took BW below, attempted hall crown on #S.

Decided to shift gears!

4th Apt: Conventional fills w/anesthetic #S/T
5th Apt: Conventional fills w/anesthetic #B/I/J

5/24/2018

MARIMNHEALTH
COEUR D'ALENE TRIBE

Recall Exams

12/10/2018

10/24/2019

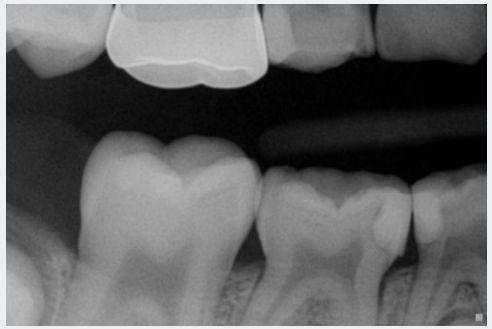

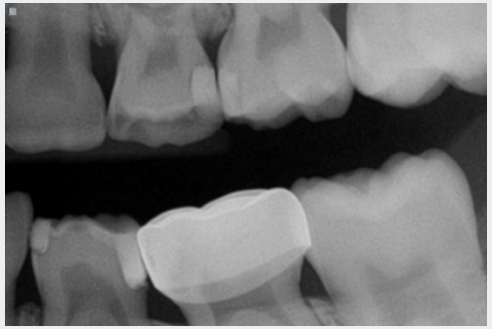

8/17/2022

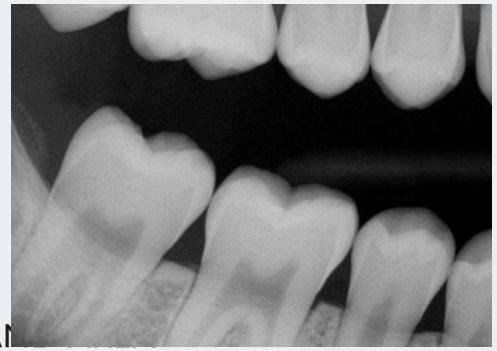

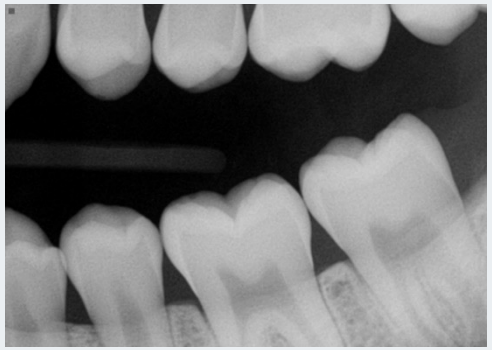

NORTHWEST PORTLAN
INDIAN HEALTH BOARD
Indian Leadership for Indian Health

MARIMNHEALTH
COEUR D'ALENE TRIBE

Lessons Learned

- Hall crowns (when successfully placed) work wonderfully!
- Improved approach to hall crowns when significant interproximal decay exists.
- Tertiary dentin formation in #L with SMART fill.

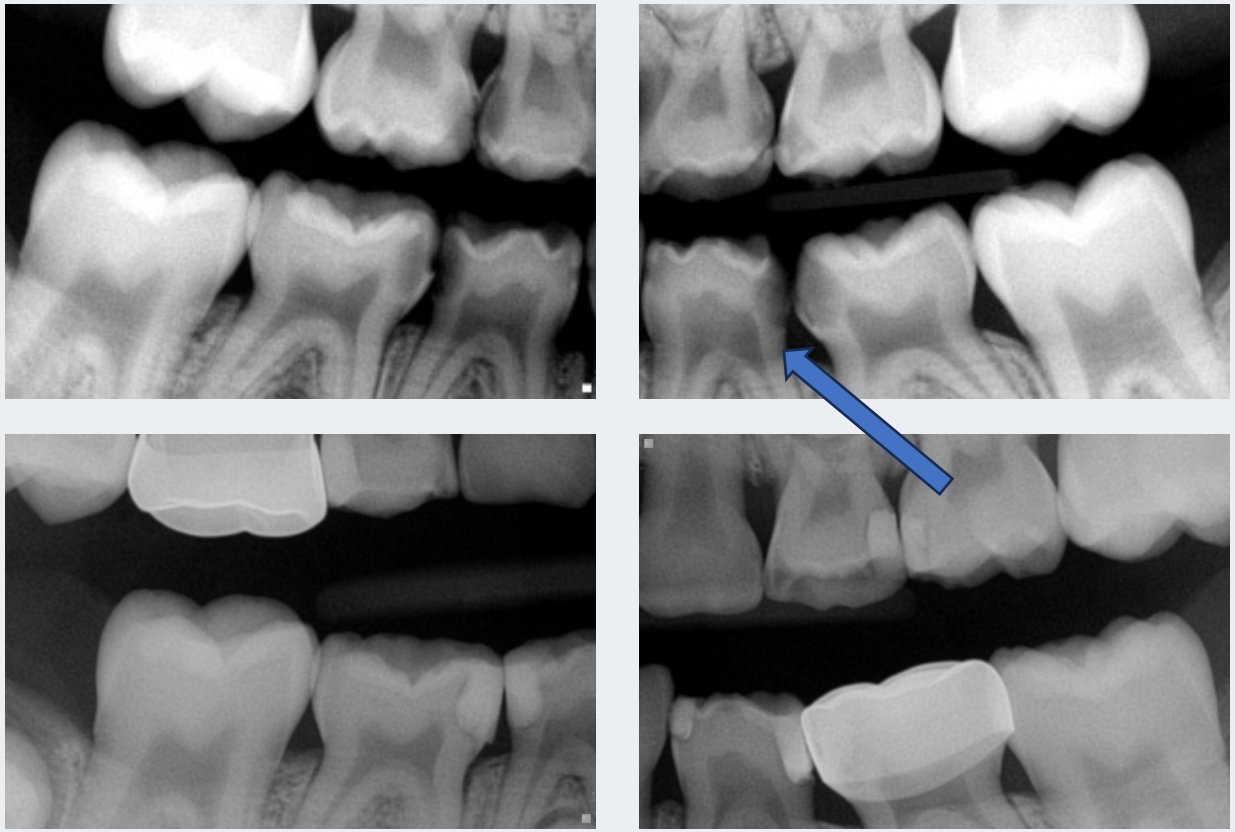

Thank You!

Indian Country Oral Health ECHO

Provided by:

Taylor Wilkens, DDS

Dental Director

Marimn Dental Clinic

Coeur d'Alene Tribe

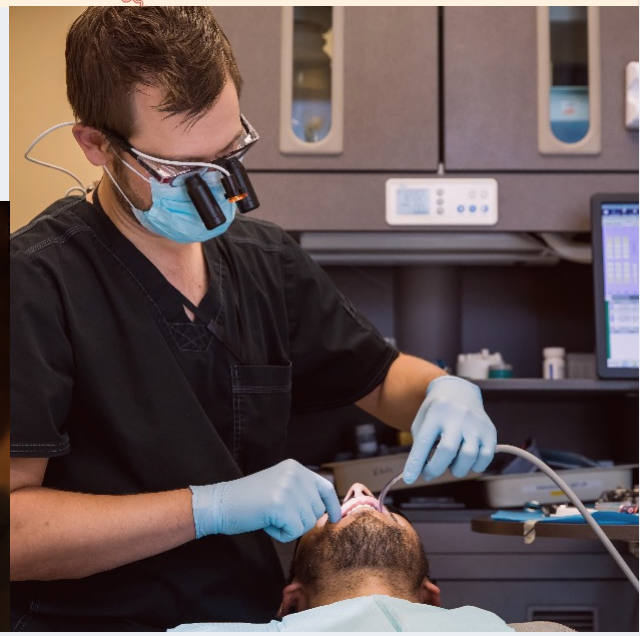

Above Image from:
https://www.marimnhealth.org/services/dental/

NORTHWEST PORTLAND AREA INDIAN HEALTH BOARD

Indian Leadership for Indian Health

Didactic Presentation

NORTHWEST PORTLAND AREA
INDIAN HEALTH BOARD
Indian Leadership for Indian Health

Hall Crowns:

National Library of Medicine
National Center for Biotechnology Information

Log in

PMC PubMed Central®

Search PMC Full-Text Archive | Search in PMC | Advanced Search | User Guide

Journal List > Dent J (Basel) > PMC7148518

As a library, NLM provides access to scientific literature. Inclusion in an NLM database does not imply endorsement of, or agreement with, the contents by NLM or the National Institutes of Health.
Learn more: PMC Disclaimer | PMC Copyright Notice

dentistry journal MDPI

Dent J (Basel). 2020 Mar; 8(1): 11.
Published online 2020 Jan 17. doi: 10.3390/dj8010011

PMCID: PMC7148518
PMID: 31963463

Hall Technique for Carious Primary Molars: A Review of the Literature

Doua H. Altoukhi[1] and Azza A. El-Housseiny[1,2,*]

Author information • Article notes • Copyright and License information PMC Disclaimer

Dent J (Basel)

Abstract

Go to:

OTHER FORMATS

PubReader | PDF (461K)

ACTIONS

Cite

Collections

SHARE

RESOURCES

Similar articles +

Cited by other articles +

Links to NCBI Databases +

https://www.ncbi.nlm.nih.gov/pmc/articles/PMC7148518/

Hall Crowns:

The Hall technique using preformed metal crowns (PMCs) was first introduced in the literature in 2006 by Dr. Norna Hall, a general dentist from Scotland. Using the Hall technique, the crown is placed without local anesthesia, caries removal, or tooth preparation. An appropriate size of PMC should be chosen and filled with glass ionomer cement. Then, the crown is fitted over the carious primary molar by either the dentist's finger pressure, or the child's biting force [14].

https://www.ncbi.nlm.nih.gov/pmc/articles/PMC7148518/

Hall Crowns:

Why does the Hall Crown technique work?

The Hall technique has very straightforward biological principles. It can arrest caries and protect the primary tooth until shedding. By using the Hall technique, the superficial plaque layer, which is the most essential layer in the biofilm for caries progression, is left and sealed along with the carious lesion. As a response, the plaque biofilm composition will be changed to a less cariogenic flora. Therefore, this technique may arrest or at least slows down caries progression in primary teeth [15].

https://www.ncbi.nlm.nih.gov/pmc/articles/PMC7148518/

Hall Crowns:

Why does the Hall Crown technique work?

The technique is aimed to increase child's compliance and operator comfort as local anesthesia is eliminated. In addition to caries sealing, it is expected that a child will have a less traumatic dental experience in his early life and he will probably return for more difficult treatment in the future [16].

https://www.ncbi.nlm.nih.gov/pmc/articles/PMC7148518/

Hall Crowns:

The Hall Crown technique

The Hall technique does not require local anesthesia, caries excavation, or tooth preparation. At the beginning, orthodontic separators should be placed between the contact point of the primary molar using two pieces of dental floss [20] or the elastic separating pliers [21]. The separators are left in place for five days. Then, after separators removal, the size of the PMC that is tight enough to give a feeling of 'spring back' during seating should be selected. Then, a glass ionomer luting cement (GIC) (Type I) is placed inside the crown, and the crown is pressed tightly until it is fully seated on the tooth. After that, the excess cement must be removed quickly.

https://www.ncbi.nlm.nih.gov/pmc/articles/PMC7148518/

Hall Crowns:

The Hall Crown technique

……(continued)
The patient is then asked to maintain biting on the crown for two minutes till the cement is completely set and the crown is fully seated in position. Finally, the remaining cement must be removed, the contact areas flossed, and the child is discharged. The child must be advised that the feeling of the crown being high during biting will be resolved within one or two days [20]. Regarding the use of orthodontic separators before placement of Hall PMCs, a Chi square analysis revealed no relationship between the use of separators and the adequate Hall crowns fit (p = 0.810) [22].

https://www.ncbi.nlm.nih.gov/pmc/articles/PMC7148518/

Hall Crowns:

Time?

There was no considerable difference in the time taken to discuss the procedure and complete it between PMCs placed by Hall technique and other restorations when they were done at a single visit. The mean time to discuss and finish the restoration was almost 11 min (range from 4 to 32 min) for the traditional restorations. However, the average time was around 12 min (range from 2 to 40 min) for the Hall crowns. For 64% of the patients, the treatments were done at one appointment and for 48% of the patients, the treatment was accomplished at separate appointments. For the 13% of the PMCs placed by Hall technique, orthodontic separators were applied, which demanded an additional visit. GDPs had a good experience in placing most of the control restorations, which explains the reduced working time [22].

https://www.ncbi.nlm.nih.gov/pmc/articles/PMC7148518/

Hall Crowns:

Indications and Contraindications of the Hall Technique

Not every child, carious primary molar in that child, or dentist is suitable for the Hall technique. In addition, application of the Hall technique ***without a comprehensive prevention program*** is unlikely to reach the goal of most pediatric dentists, which is, having carious primary teeth that exfoliate with the minimum risk of infection or pain [20]. Indications and contraindications for the use of the Hall technique are listed in Table 1.

https://www.ncbi.nlm.nih.gov/pmc/articles/PMC7148518/

Hall Crowns:

Indications and Contraindications of the Hall Technique

Table 1

Hall technique indications and contraindications for carious primary molars.

Indications of the Hall Technique
1. Teeth with occlusal caries, non-cavitated, if the patient is unable to accept fissure sealant, partial caries removal or conventional restoration [20].
2. Teeth with proximal caries either cavitated or non-cavitated if the patient is unable to accept partial caries removal, or conventional restoration [20].
3. Hall technique is mostly indicated to be used in routine general dental practice [20].
Contraindications of the Hall Technique
1. Tooth with signs or symptoms of dental infection or irreversible pulpitis [20].
2. Crowns severely destructed with caries, which considered non-restorable [20].
3. Very young children who do not understand the procedure or tolerate biting the crown into its position without local anesthesia [14,23].

https://www.ncbi.nlm.nih.gov/pmc/articles/PMC7148518/

Hall Crowns:

Advantages of the Hall Technique

Table 2

Advantages of the Hall Technique for managing carious primary molars.

Advantages of the Hall Technique
1. It is a non-invasive procedure in which the crown is cemented without local anesthesia, caries excavation, or tooth preparation [23].
2. It is a quick procedure that limits child's anxiety [24].
3. It is considered as a less traumatic technique for the child [23].
4. It seals in carious lesion and could arrest caries or at least slow it down [15].
5. It improves pulpal health [23].
6. It increases the access to dental care, decrease percentages of untreated dental caries and deliver a restoration that will permit natural tooth exfoliation [24].
7. It is more cost-effective than conventional restorations [25,26].
8. If done at a single visit, the time needed to complete the procedure is minimal [22].

https://www.ncbi.nlm.nih.gov/pmc/articles/PMC7148518/

Hall Crowns:

Concerns of the Hall Technique

The Hall technique has some concerns regarding its use. The technique is time consuming, as orthodontic separators are needed, which indicates an additional visit. It does not include occlusal preparation before cementation of the crown. This could lead to premature contacts after crown cementation and increase occlusal vertical dimensions (OVDs). However, adequate occlusal contacts are re-established at the recall visit after 1 year [23]. Furthermore, children need to withstand biting a rigid metal crown into its place, across relatively tight contact points, with no local anesthesia [14]. Moreover, metal crowns are not cosmetically acceptable to the child or the parents [12,27].

https://www.ncbi.nlm.nih.gov/pmc/articles/PMC7148518/

Hall Crowns:

Concerns of the Hall Technique: Aesthetics

…aesthetic problems related to PMCs placed by the Hall technique can be a concern of patients and their parents compared to conventional aesthetic restorations. Some studies reported that one of the reasons specified by dental practitioners for not using stainless steel crowns for multi-surface carious lesions, extensive dental caries, and after pulpal treatment, was because PMCs are not aesthetically acceptable to the parent or child, although most dentists recognized that crowns are the most durable restoration for primary molar teeth [12,27]. Although some parents complained from the aesthetics of metal crowns, once the dentist explained all the advantages to the parents, they agreed with the treatment [12].

https://www.ncbi.nlm.nih.gov/pmc/articles/PMC7148518/

Hall Crowns:

Concerns of the Hall Technique: Occlusal Vertical Dimension (OVD)

According to Innes et al., the occlusion equilibrates rapidly, usually within few weeks [14]. Though it is better to follow up the child two weeks following placement of the crown to evaluate the occlusion, it was not possible due to the limitations of the general dental practice setting. Forming a perfect research design within the general dental practice environment was considered one of the research challenges [22].

It has been shown that there were no children who re-attended the clinic after using Hall technique with signs of occlusal problems and TMJ dysfunctions, or difficulty during eating at one or two-year recall visits [22]. In addition, OVDs were spontaneously corrected after almost 30 days following placement of crowns by the Hall technique [28].

https://www.ncbi.nlm.nih.gov/pmc/articles/PMC7148518/

Hall Crowns:

Concerns of the Hall Technique: Occlusal Vertical Dimension (OVD)

According to Innes et al., the occlusion equilibrates rapidly, usually within few weeks [14]. Though it is better to follow up the child two weeks following placement of the crown to evaluate the occlusion, it was not possible due to the limitations of the general dental practice setting. Forming a perfect research design within the general dental practice environment was considered one of the research challenges [22].

It has been shown that there were no children who re-attended the clinic after using Hall technique with signs of occlusal problems and TMJ dysfunctions, or difficulty during eating at one or two-year recall visits [22]. In addition, OVDs were spontaneously corrected after almost 30 days following placement of crowns by the Hall technique [28].

https://www.ncbi.nlm.nih.gov/pmc/articles/PMC7148518/

Hall Crowns:

Concerns of the Hall Technique, Occlusal Vertical Dimension (OVD)

Orthodontists regularly treat patients with bite planes anteriorly or posteriorly, which significantly increase the OVDs compared to Hall crowns. These appliances do not increase the risk of TMJ disorders when placed in a healthy child [29].

https://www.ncbi.nlm.nih.gov/pmc/articles/PMC7148518/

Hall Crowns:

Concerns of the Hall Technique, Occlusal Vertical Dimension (OVD)

(a) (b) (c)

Figure 1

A four-year-old boy treated with Hall preformed metal crowns (PMCs) showing: (**a**) A pre-treatment lateral photograph showing the patient's occlusion, (**b**) a post-treatment lateral photograph showing the patient's occlusion (taken immediately after cementation of the last PMC), and (**c**) a one-year-recall photograph showing correction of the OVD.

https://www.ncbi.nlm.nih.gov/pmc/articles/PMC7148518/

Hall Crowns:

Hall Technique Versus Traditional Crown Preparation

Supporting the results of Ludwig et al. [24], Elamin et al. in 2019 found that the survival rate of both the Hall technique and the traditional crown technique were high (above 90%) after two years, with no statistically significant difference. The survival rate after one year was also high for both techniques—it was 94.5% for the Hall technique and 96% for traditional crown technique. There were 2.7% minor failures and 6.4% major failures in the Hall technique. However, 5.8% minor failure and 5.8% major failure were seen in the traditional crown technique. Minor failures included perforation or dislodgement of the SSCs without pain. Conversely, major failures include teeth that with pain that needed pulp therapy or extraction [32]. From the previous studies, we can infer that PMCs placed using the Hall technique or conventional crown technique have excellent survival rate.

https://www.ncbi.nlm.nih.gov/pmc/articles/PMC7148518/

Hall Crowns:

Hall Technique Versus Other Restorations or Non-Restorative Approach

A split mouth randomized controlled clinical trial studied the clinical effectiveness of conventional restorations (control) placed in decayed primary molars, and crowns placed by Hall technique on the contralateral molars (matched radiographically and clinically) by GDPs, with a minimum recall period of 23 months. Conventional restorations that were used are: Amalgam, composite, compomer, glass ionomer, and fissure sealant. Success or failure of the used restorations and crowns were assessed using the usual clinical criteria, as listed in Table 3 [22].

https://www.ncbi.nlm.nih.gov/pmc/articles/PMC7148518/

Hall Crowns:

Hall Technique Versus Other Restorations or Non-Restorative Approach

Table 3

Success and failure criteria of conventional restorations and the Hall technique crowns according to Innes et al. [22].

	Criteria
Success	1. Restorations or crowns appear satisfactory and no interventions were required. 2. No clinical or radiographic signs of any pulp disease. 3. Normal tooth exfoliation.
Minor Failure	1. Secondary caries, or new caries radiographically or clinically. 2. Restoration fracture or wear that requires intervention. 3. Restoration or crown loss, while the tooth was considered restorable. 4. Reversible pulpitis that does not require pulpotomy or extraction.
Major Failure	1. An abscess or an irreversible pulpitis indicating extraction or pulpotomy. 2. An inter-radicular radiolucency or an internal root resorption. 3. If the restoration or crown was lost, or the tooth was non-restorable.

https://www.ncbi.nlm.nih.gov/pmc/articles/PMC7148518/

Hall Crowns:

Hall Technique Versus Other Restorations or Non-Restorative Approach

The results of the above clinical trial showed that the success rates of the PMCs placed by the Hall technique were greater than the control restorations. Criteria of major failures were seen in 15% of control restorations. However, they were seen in only 2% of Hall crowns ($p < 0.000$). Furthermore, criteria of minor failures were noticed in 46% of control restorations but only in 5% of Hall crowns ($p < 0.000$). Pain from the restored tooth was demonstrated in 11% of control restorations, while it was seen in 2% of Hall crowns ($p = 0.003$) [22].

22. Innes N.P., Evans D.J., Stirrups D.R. The Hall Technique; a randomized controlled clinical trial of a novel method of managing carious primary molars in general dental practice: Acceptability of the technique and outcomes at 23 months. *BMC Oral Health.* 2007;7:18. doi: 10.1186/1472-6831-7-18.

https://www.ncbi.nlm.nih.gov/pmc/articles/PMC7148518/

Hall Crowns:

Hall Technique Versus Other Restorations or Non-Restorative Approach

Table 4

Success rate success rates of different caries management approaches.

Caries Management Approaches	Success Rate	Follow-Up
Hall Technique	94.5% [32]	1 year [32]
	97% [24]	15 months [24]
	73.4% [14]	3 years [14]
	94% [24]	53 months [24]
	67.6% [14]	5 years [14]
Traditional Crown Preparation	96% [32]	1 year [32]
Composite	78% [37]	3 years [37]
Glass Ionomer	65% [37]	3 years [37]
	32% [37]	5 years [37]

https://www.ncbi.nlm.nih.gov/pmc/articles/PMC7148518/

Silver Diamine Fluoride (SDF):

SDF is a basic solution (pH of 10-12) with a 38% w/v Ag(NH3)2F. The silver functions as an antimicrobial, while fluoride is present in sufficient concentration to promote remineralization;[2,3] the ammonia (NH3) present stabilizes the solution.[1]

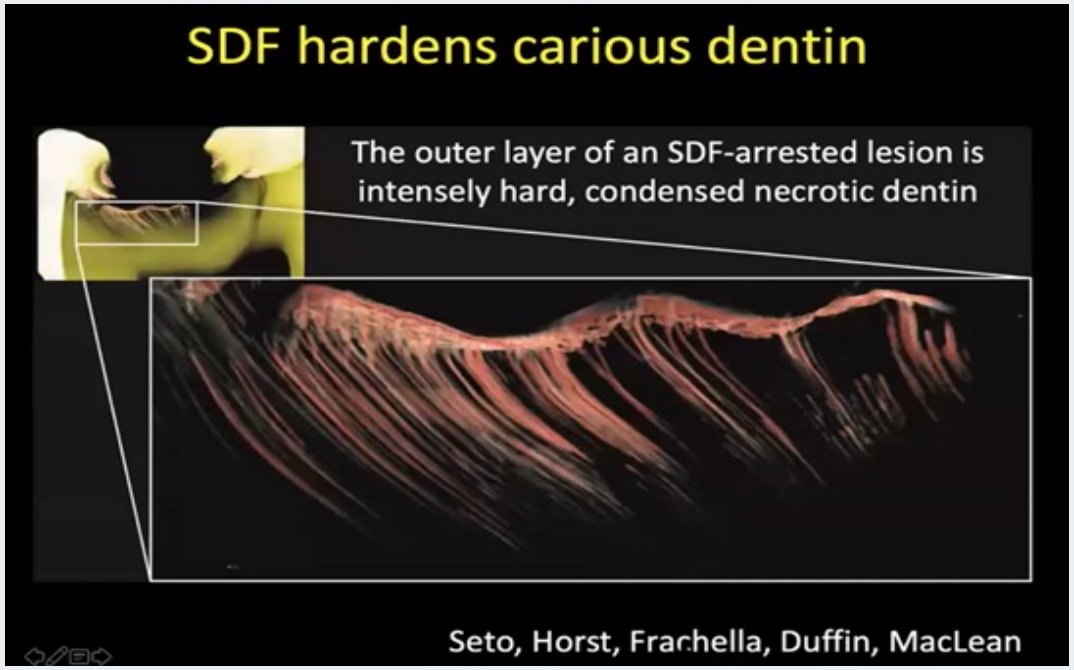

1.-Horst JA, Ellenikiotis H, Milgrom PL. UCSF protocol for caries arrest using silver diamine fluoride: rationale, indications and consent. J Calif Dent Assoc 2016;44(1):16-28.
2.Crystal YO, Niederman R. Evidence-Based Dentistry Update on Silver Diamine Fluoride. Dent Clin North Am 2019;63(1):45-68.
3.Mei ML, Lo ECM, Chu CH. Arresting Dentine Caries with Silver Diamine Fluoride: What's Behind It? J Dent Res 2018;97(7):751-58.

https://www.ada.org/resources/research/science-and-research-institute/oral-health-topics/silver-diamine-fluoride#:~:text=The%20U.S.%20Food%20and%20Drug,and%20must%20be%20professionally%20applied.

Silver Diamine Fluoride (SDF):

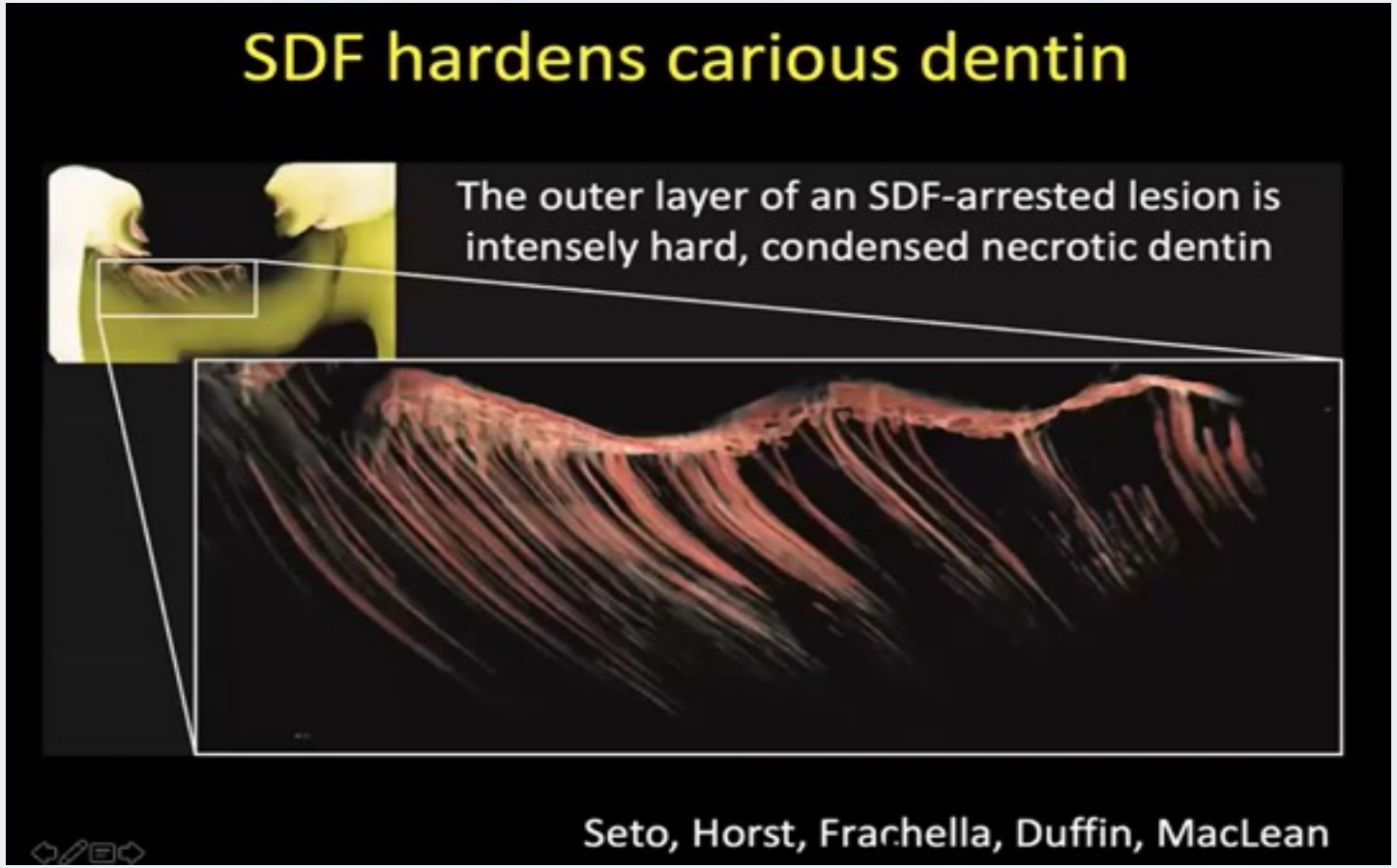

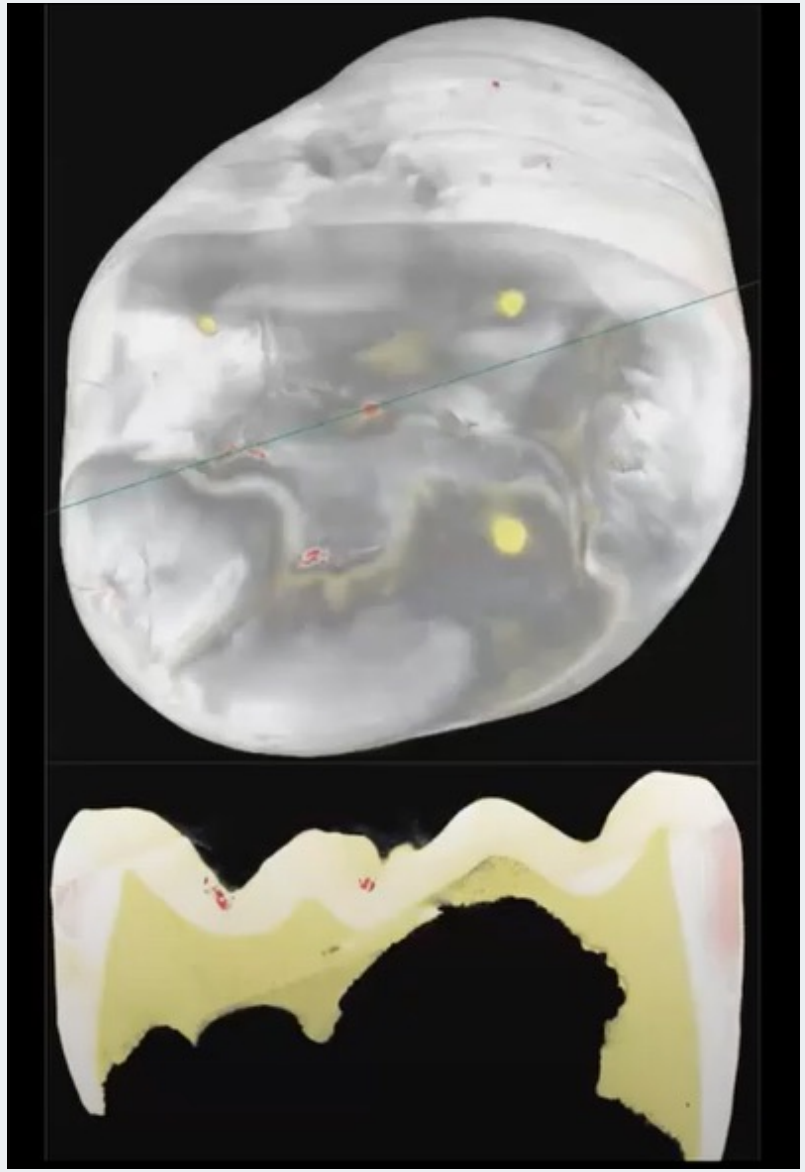

NORTHWEST PORTLAND AREA
INDIAN HEALTH BOARD
Indian Leadership for Indian Health

Silver Diamine Fluoride (SDF):

Silver Diamine Fluoride: What Is Its Place In Oral Healthcare? (AAPD: SDF White Paper Final)

The black stained layer that has been associated with arrested dentin caries shows a hard and impermeable layer of silver phosphate that protects collagen exposure.

Chu, C. H., Mei, L., Seneviratne, C. J., & Lo, E. C. M. (2012). Effects of silver diamine fluoride on dentine carious lesions induced by Streptococcus mutans and Actinomyces naeslundii biofilms. International Journal of Paediatric Dentistry, 22(1), 2-10.

https://www.aapd.org/assets/1/7/SDF_White_Paper_Final.pdf

2018 2021

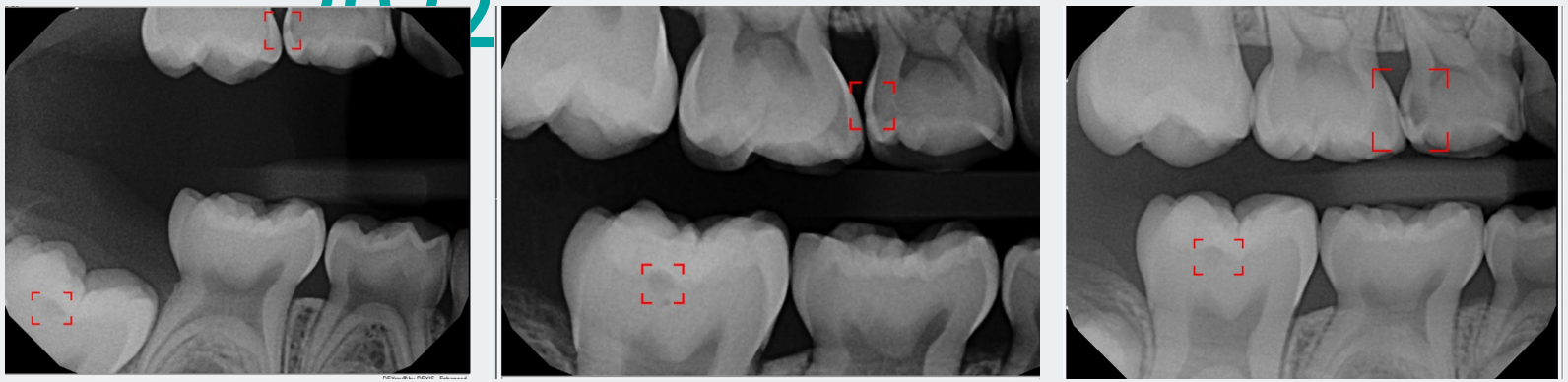

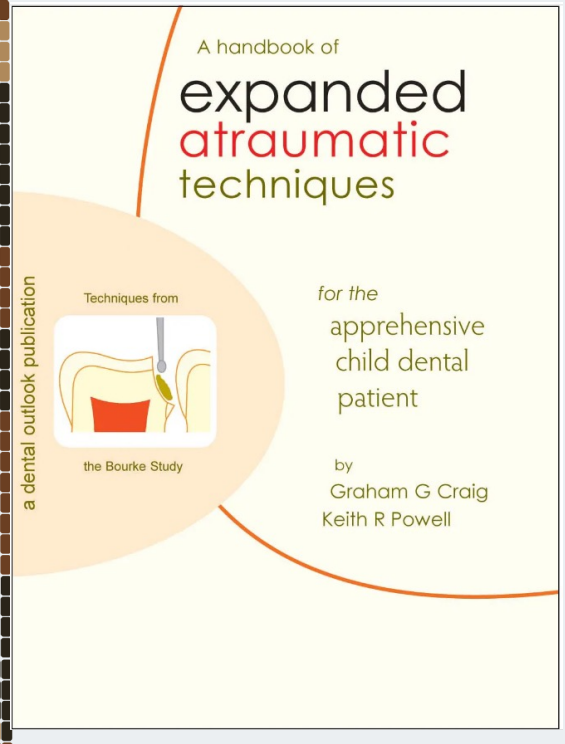

Likelihood of SDF Caries Arrest = Cleansability

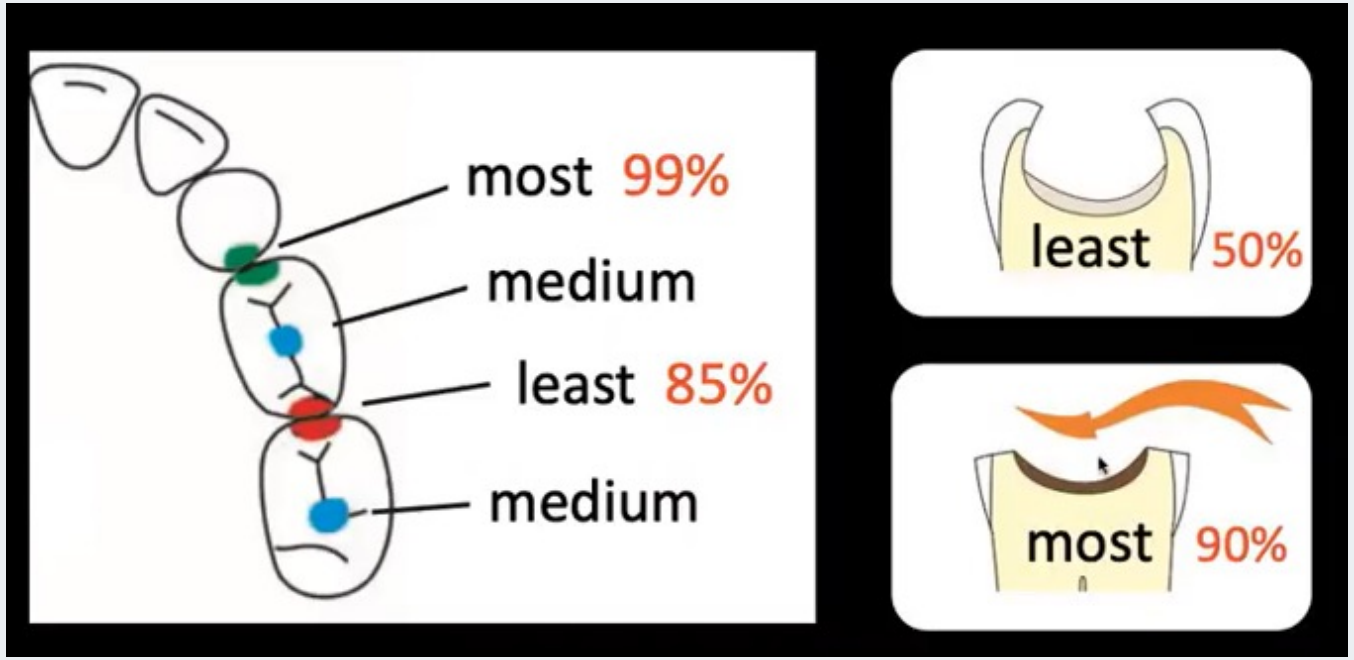

Craig and Powell, Dental Outlook. 2013

NORTHWEST PORTLAND AREA
INDIAN HEALTH BOARD
Indian Leadership for Indian Health

Silver Diamine Fluoride (SDF):

Effectiveness?

When applied to a carious lesion, SDF has also been shown to decrease caries risk of adjacent tooth surfaces. (ADA)

Llodra JC, Rodriguez A, Ferrer B, et al. Efficacy of silver diamine fluoride for caries reduction in primary teeth and first permanent molars of schoolchildren: 36-month clinical trial. J Dent Res 2005;84(8):721-4.



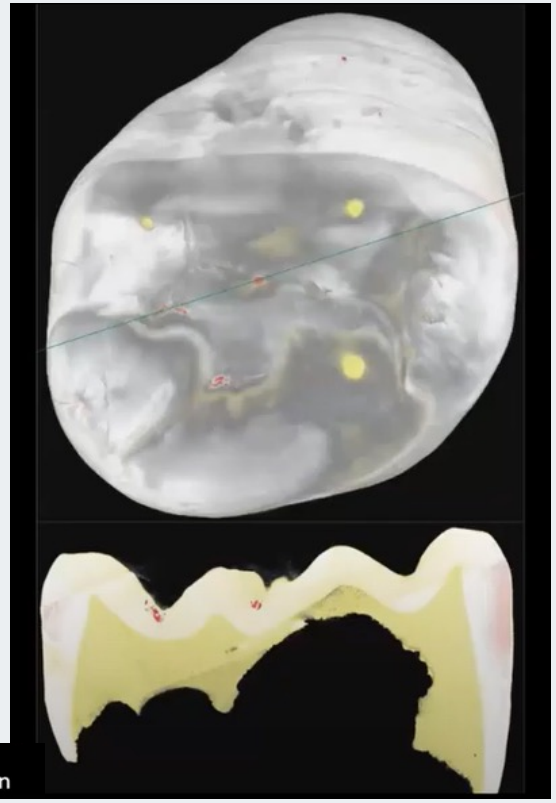

Seto, Horst, Frachella, Duffin, MacLean

https://www.ada.org/resources/research/science-and-research-institute/oral-health-topics/silver-diamine-fluoride#:~:text=The%20U.S.%20Food%20and%20Drug,and%20must%20be%20professionally%20applied.

Silver Diamine Fluoride (SDF):

Silver Diamine Fluoride: What Is Its Place In Oral Healthcare?
(AAPD: SDF White Paper Final)

Effectiveness?

Studies have shown that SDF does not induce inflammation or necrosis of the pulp and adequate tertiary dentin can be induced, therefore, making it a potentially adequate indirect pulp therapy material for deep cavities

Korwar, A., Sharma, S., Logani, A., & Shah, N. (2015, July 31). Pulp response to high fluoride releasing glass ionomer, silver diamine fluoride, and calcium hydroxide used for indirect pulp treatment: An invivo comparative study. 6(3), 288-292. Retrieved September 15, 2016, from http://www.contempclindent.org/article.asp?issn=0976-237X;year=2015;volume=6;issue=3;spage=288;epage=292;aulast=Korwar

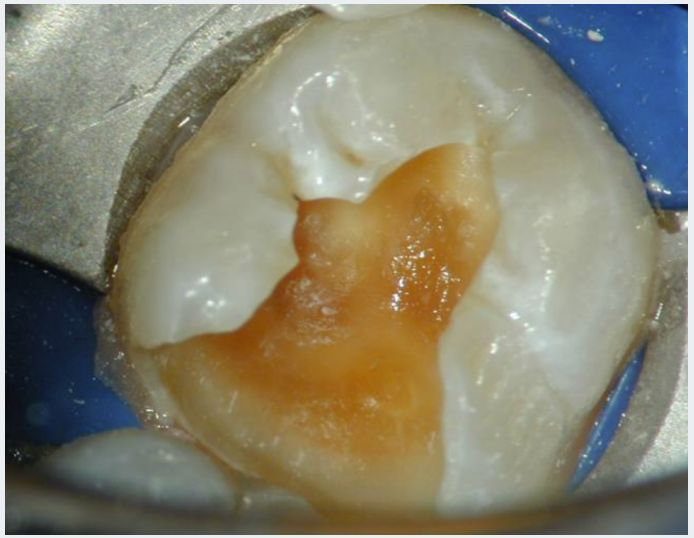

https://www.aapd.org/assets/1/7/SDF_White_Paper_Final.pdf

Silver Diamine Fluoride (SDF):

Application

Dosage and Administration: 1. Isolate the affected area of the tooth with cotton rolls or protect the gingival tissue of the affected tooth with petroleum jelly. Alternatively, a rubber dam can be used to isolate the area. 2. Clean and dry the affected tooth surface. 3. For up to 5 treated sites per patient, dispense 1-2 drops of solution into a disposable dappen dish. Transfer material directly to the tooth surface with an applicator. 4. Allow to air dry, do not rinse. If needed, one or two reapplications may be administered at intervals of one week.

Dosage and Administration:

1. Isolate the affected area of the tooth with cotton rolls or protect the gingival tissue of the affected tooth with petroleum jelly. Alternatively, a rubber dam can be used to isolate the area.
2. Clean and dry the affected tooth surface.
3. For up to 5 treated sites per patient, dispense 1-2 drops of solution into a disposable dappen dish. Transfer material directly to the tooth surface with an applicator.
4. Allow to air dry, do not rinse.

If needed, one or two reapplications may be administered at intervals of one week.

How Supplied: Single 10 mL dropper-bottle containing 8 mL of product. Not sterile.

Storage: Do not freeze or expose to extreme heat. Keep in an air-tight container in a dark place.

Caution: Federal law restricts this device to sale by or on the order of a dentist or physician.

Distributed by:
Elevate Oral Care, LLC.
West Palm Beach, FL 33411
877-866-9113

https://www.elevateoralcare.com/Application-Downloads

Hall Crowns:

The Big Picture!

The need for alternative treatment modalities for decayed primary molars, such as the Hall technique or a prevention-only approach, might be questioned. This is due to the available conventional options with proven efficacy which are parts of standard teaching in all dental collages. Nevertheless, these techniques necessitate an early diagnosis by radiographs, followed by conventional restorations using local anesthesia and high-speed hand pieces which are not always applied in the primary care setting. ***Ideally, every child must have access to restorative and preventive care of great quality, but until that time arrives, there is still a need for alternative techniques that are easier and more acceptable to dentists, children, and their parents*** [14].

https://www.ncbi.nlm.nih.gov/pmc/articles/PMC7148518/

Group Discussion and Q & A

NORTHWEST PORTLAND AREA
INDIAN HEALTH BOARD
Indian Leadership for Indian Health

Questions?

NORTHWEST PORTLAND AREA
INDIAN HEALTH BOARD
Indian Leadership for Indian Health

Dr. Sean Kelly: drkelly55@gmail.com
Dr. Miranda Davis: mdavis@npaihb.org

Thank You!

Course #	Course Name	Date(s)	Completion Code	Status
DE0898	Indian Country Oral Health ECHO [January 2024, Live Webinar]	1/10/2024 - 1/10/2024	Michigan	Available
DE0899	Indian Country Oral Health ECHO [January 2024, Recorded]	1/24/2024 - 1/23/2027	Michigan	Final

NORTHWEST PORTLAND AREA
INDIAN HEALTH BOARD
Indian Leadership for Indian Health