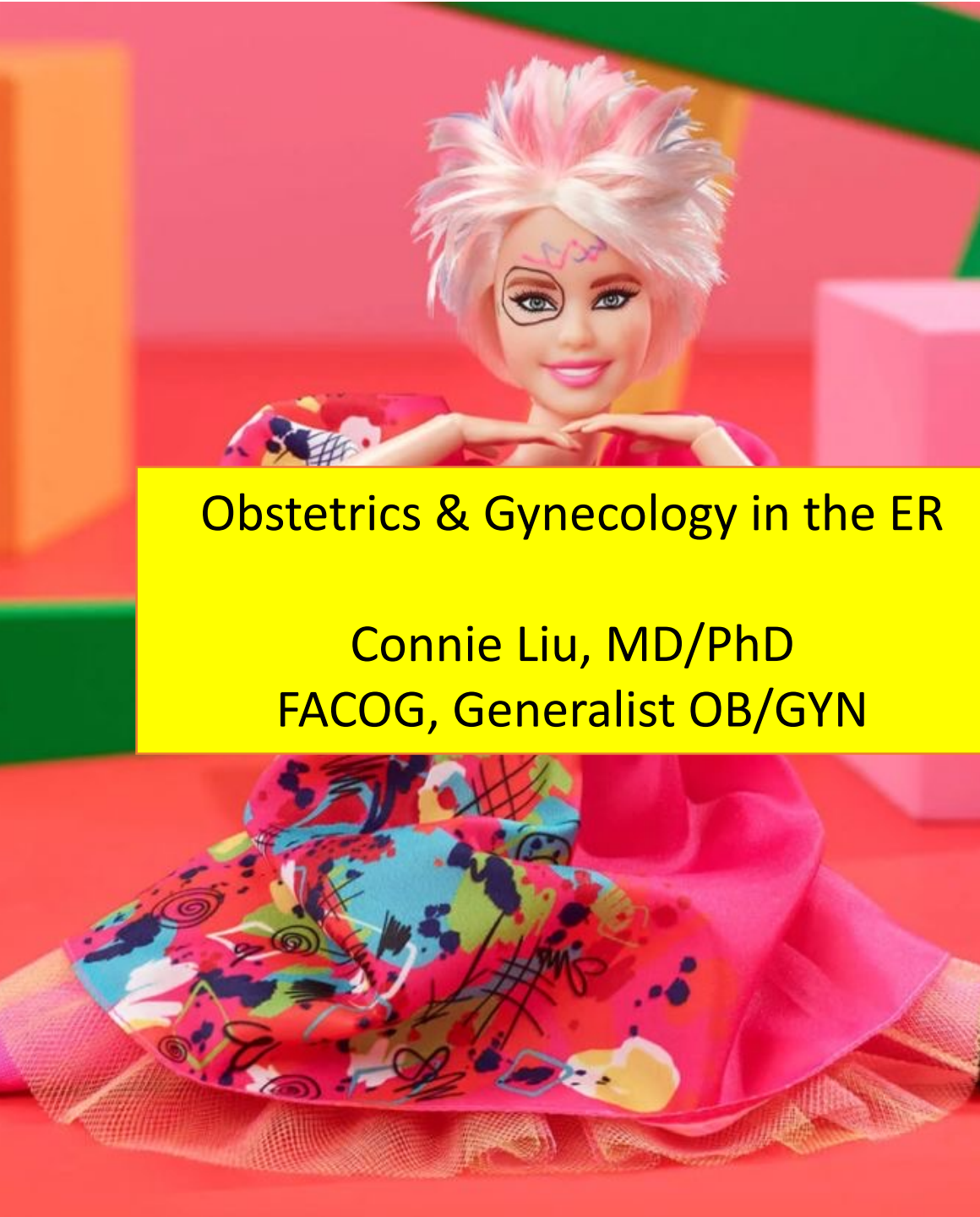
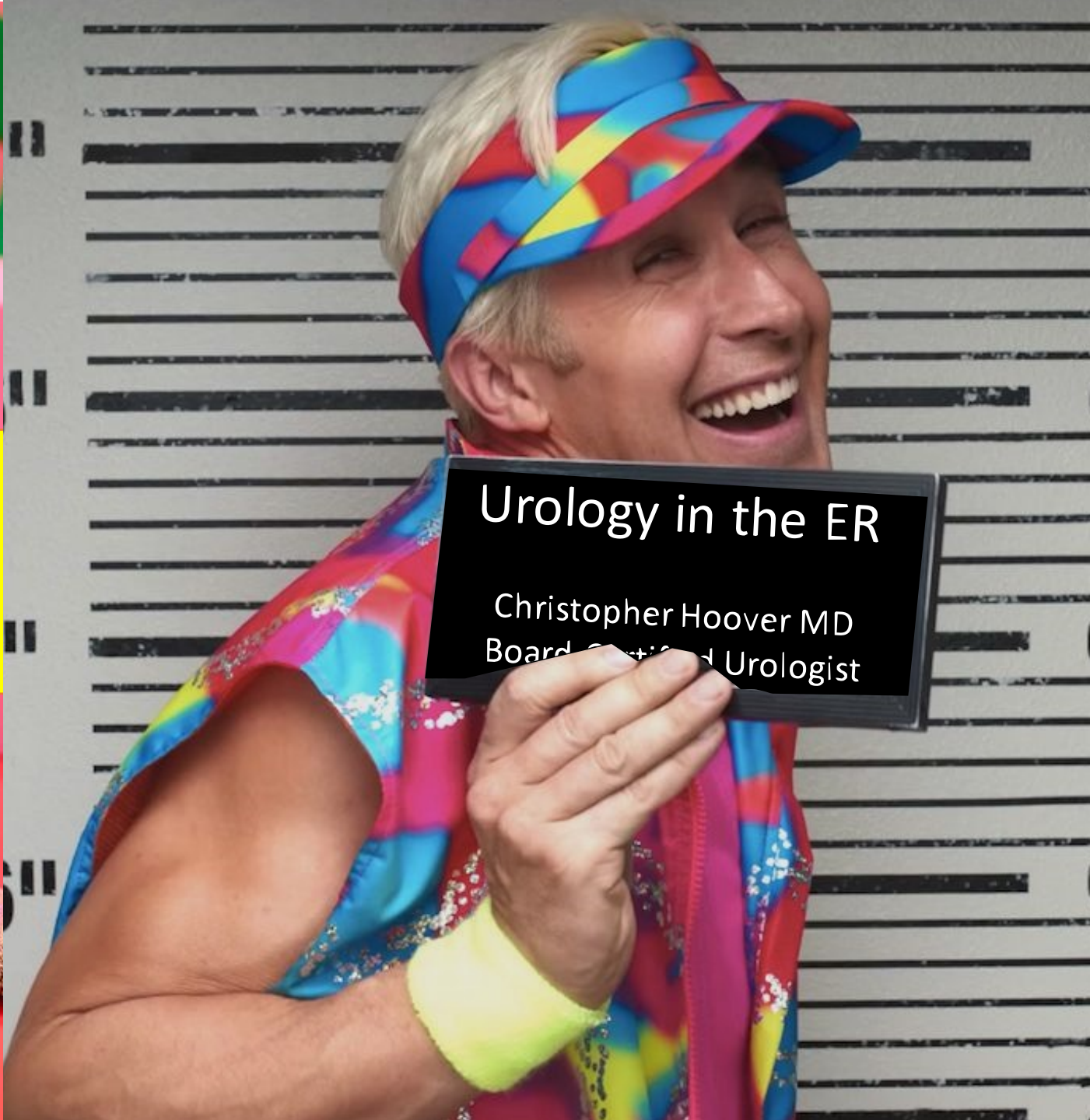
Obstetrics & Gynecology in the ER

Connie Liu, MD/PhD
FACOG, Generalist OB/GYN



Urology in the ER

Christopher Hoover MD
Board Certified Urologist



Disclosures CRVH

- No industry/corporate relationships – married to CWL
- Urologist at Rehoboth McKinley Christian Healthcare Services in Gallup, NM
- IT Director, Board member at Gallup Community Health (FQHC LAL)

Goals

- Practical advice
- Brief literature review
- Not be boring

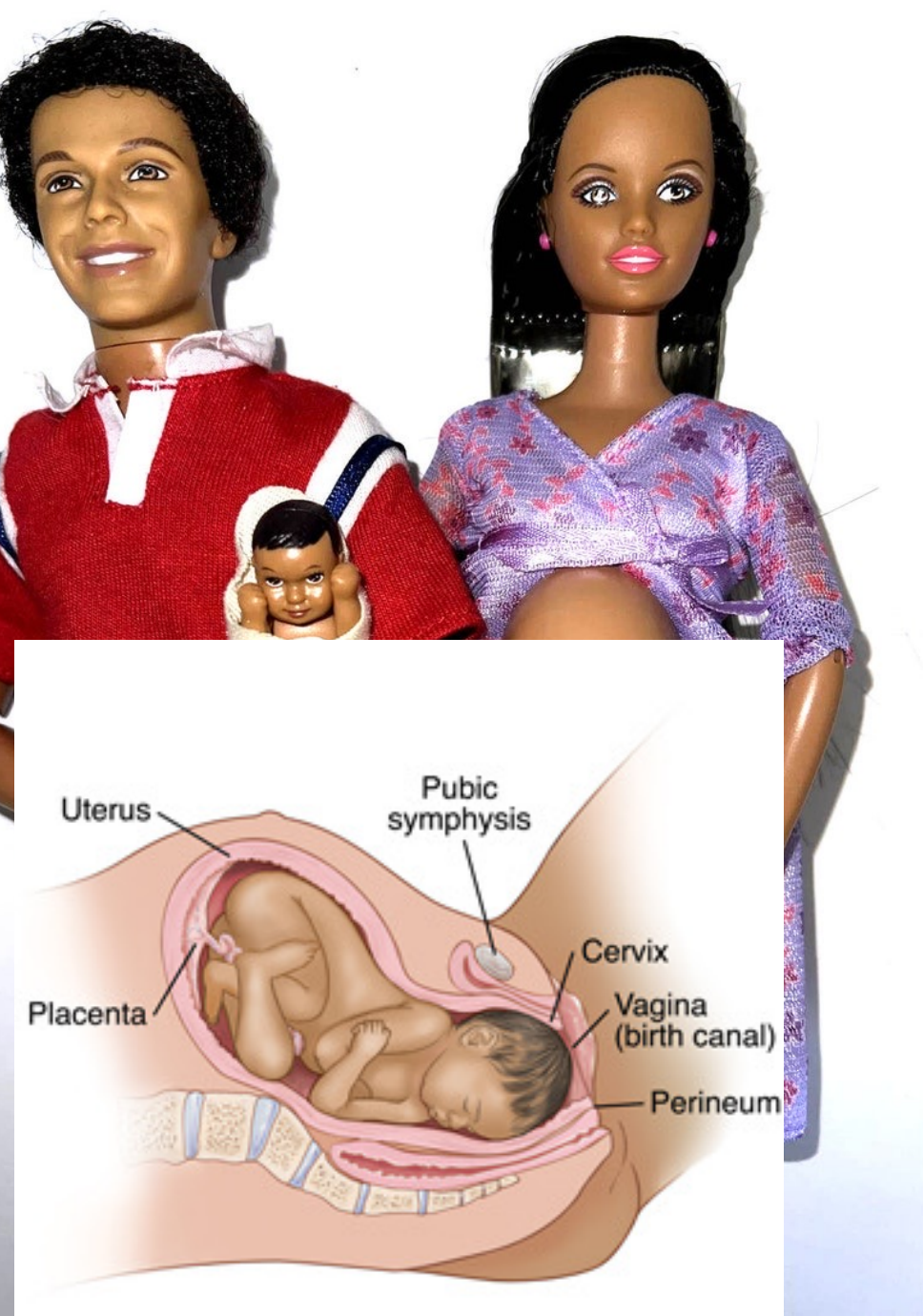
A scene from the movie Barbie featuring Barbie and Ken. Barbie is in the driver's seat of a pink convertible car, wearing a pink beret and a pink dress with a large bow. Ken is in the passenger seat, wearing a pink patterned shirt. They are both holding a pair of bright yellow roller skates with pink laces. The background is a bright, sunny outdoor setting with a pink sign that says "Barbie" in a stylized font.

Disclosures CWL

- No industry/corporate relationships – married to CRVH
- Medical Officer at Gallup Indian Medical Center in Gallup, NM

Goals

- General pearls and reframe
- Review of emergencies
- Be memorable



When a Pregnant Patient Walks In:

ASK:

1. Parity
2. Gestational age
3. Prenatal care vs no prenatal care
4. The Big Four: Contractions? Rupture of membranes? Bleeding? Fetal Movement?

EVALUATE:

1. Palpable contractions?
2. Vaginal exam – Cervix, Presenting Part?
3. Ultrasound - Position (vertex?)
4. Ultrasound vs. stethoscope vs. doppler – 2 minute FHR

Is Delivery Imminent? – Where is my kit?

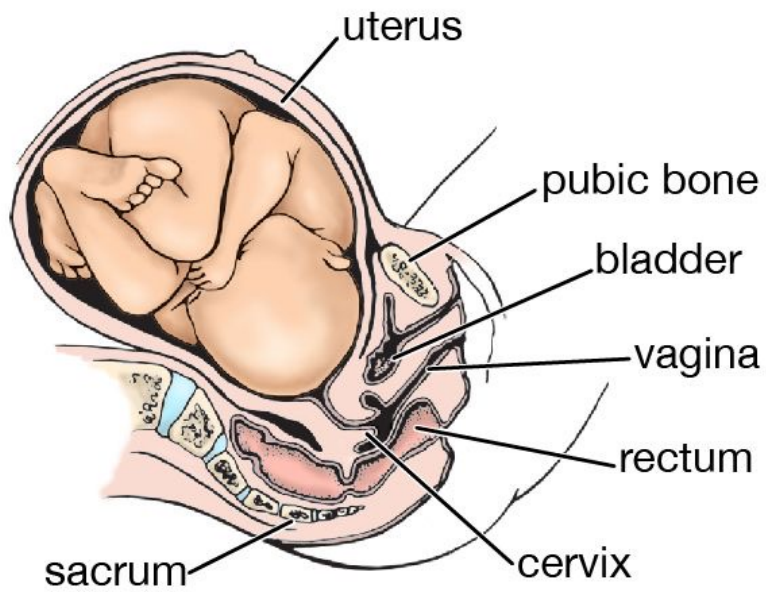
Prepare for Mom

- Sterile gloves and gown
- Sterile towels
- 2 umbilical clamps/kellys
- Sterile scissors
- Hemorrhage meds

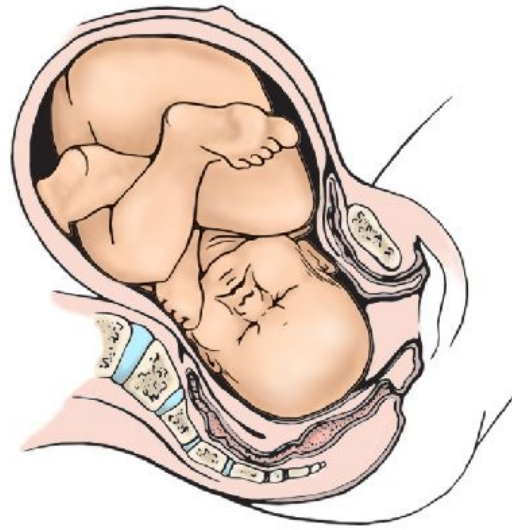
Prepare for Baby

- Blankets
- Suction
- Cardiorespiratory monitor
- Airway equipment

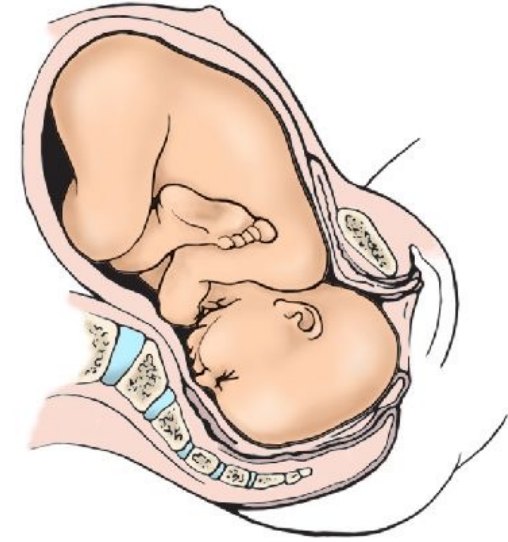Onset of labour



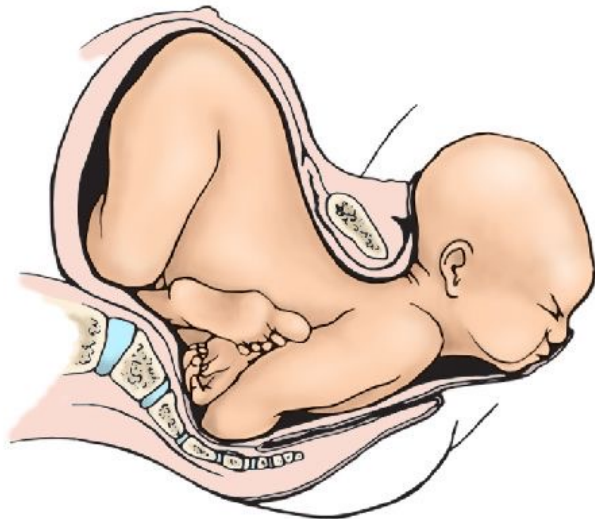Flexion



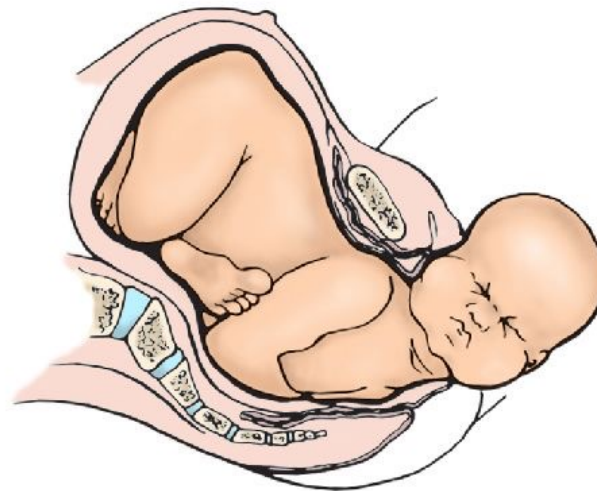
Internal rotation of head



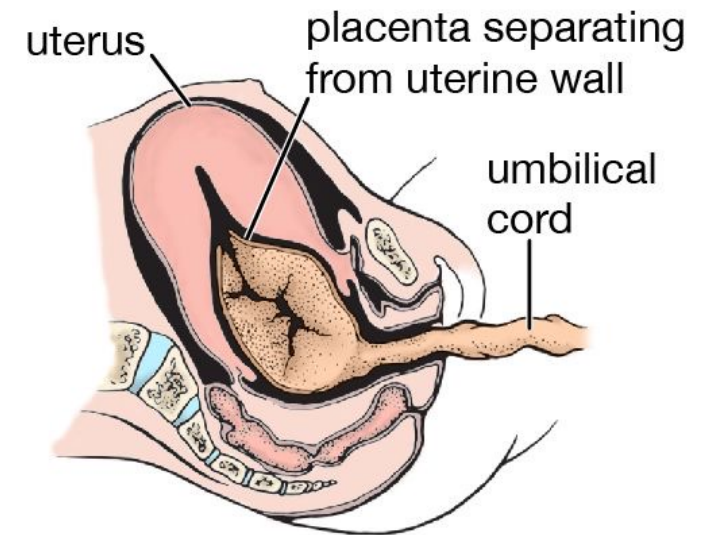
Extension



External rotation of head



Uterus immediately after birth



EMERGENT DELIVERY PEARLS

Cord Prolapse – the cord is compressed by the presenting part

| | |
|---------------------|---|
| Decompress the cord | - Hold the presenting part above the cord |
|---------------------|---|

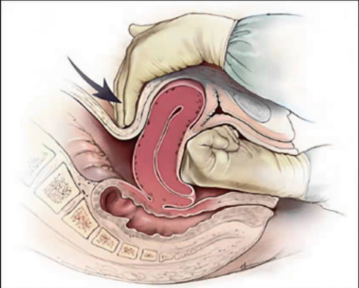
Should Dystocia - baby's shoulder is stuck under the pubic bone

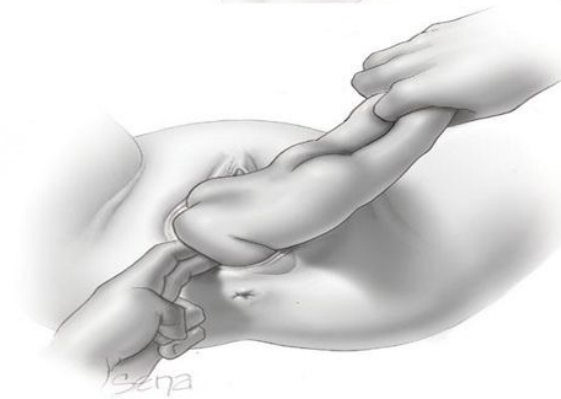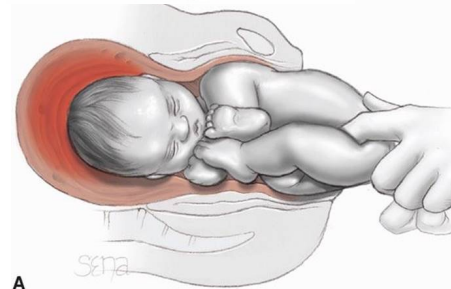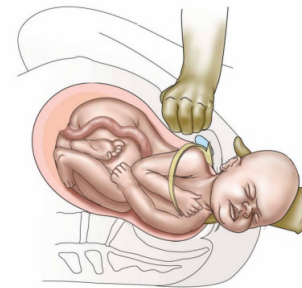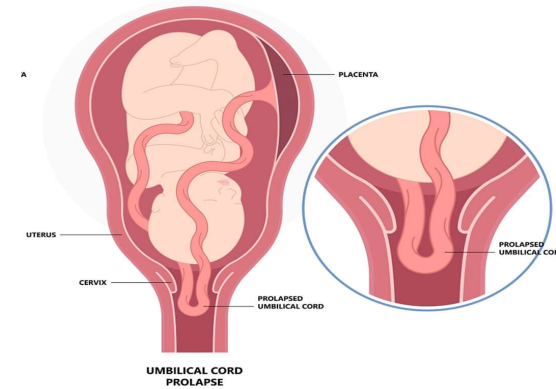
| | |
|--------------------------------------|---|
| Remove anything that blocks your way | - Deep flexion of hips (McRoberts) - Empty the bladder |
| Move the baby | - Suprapubic pressure - Rotate the baby by pushing the shoulder - Deliver the posterior arm |

Breech Delivery – be patient

| | |
|--|---|
| Deliver the limbs Baby delivers face-down | - Deliver limbs by sweeping across the body - Support the body to gently deliver |
|--|---|

Postpartum Hemorrhage – where is my algorithm?

| | | | |
|---|--|---|--|
| Contract uterus Fix other causes Replete volume | - MECHANICAL - Uterine fundal massage - Bakri balloon, Bimanual massage |  | - MEDS - Oxytocin 10U IM (NOT IV PUSH) v. bolus (rule of thumb – 10U in 30 min); - TXA 1g q 30 min; - Methergine 10 mg IM (q2 hr) - HTN - Hemabate 250 mcg (q 15 min) – asthma - Misoprostol 800 mcg buccal vs. rectal |
| | - ACTIVATE MASSIVE TRANSFUSION PROTOCOL | | |



Obstetric Hemorrhage Flowsheet

| | <u>Stage 1</u> | <u>Stage 2</u> | <u>Stage 3</u> |
|-------------------------|---|---|--|
| | QBL >1000 mL or VS changes (by >15% or HR ≥ 110, BP ≤ 85/45, O2 sat < 95%) | QBL >1000 mL and continued bleeding but <1500 mL | QBL >1500 mL or >2u pRBCs given or VS unstable or suspicion of DIC |
| <u>Assessment</u> | Notify charge RN, CNM Place pulse ox VS, O2 sat Q5min Weigh + record cumulative blood loss Q5-15m Careful inspection w/ good exposure of vagina, cervix, uterus, placenta | Call MD Call Obstetric Hemorrhage Response Team-SVD Continue cumulative QBL STAT CBC, coags Move US machine to room Consider moving to OR and calling anesthesia Consider amniotic fluid embolism, uterine inversion | Call Obstetric Hemorrhage Response Team - C-section Consider calling OR staff Consider calling 2nd MD Repeat STAT CBC, coags, draw ABG Consider central line |
| <u>Meds/ Procedures</u> | IV access: at least 18g Bolus pitocin bag, may repeat x1 Repeat fundal massage Methergine 0.2mg IM x1 unless hypertensive (May rpt x1 if good response, otherwise move on to 2nd line uterotonic) Place foley | 2nd line uterotonics: hemabate 250mcg IM OR misoprostol 800mcg SL TXA 1g/100cc NS over 10 min, may rpt x1 after 30m Place 2nd IV Vaginal: Repair lacs, D&C for retained placenta, consider Bakri CS: Inspect broad ligament, posterior uterus, retained placenta; consider B-lynch, Bakri | Consider activating massive transfusion protocol Consider laparotomy with B-lynch or hyst Give warmed fluids, warm blankets to upper body, SCDs |
| <u>Blood bank</u> | Crossmatch 2u pRBCs | 2u pRBCs to bedside, transfuse per VS - USE RAPID TRANSFUSER-transfusion rate per provider Order 2 FFP & crossmatch additional 2u pRBCs RN to bring blood up from blood bank | Transfuse aggressively 1:1 pRBCs:FFP |

Gross Hematuria

- Painless?

- Imaging & referral
- PVR
 - Not all hematuria needs a catheter

- Most common causes (outside of ER)

- BPH
- Atrophic vaginitis

- Painful?

- Stone
 - Low-dose CT or KUB+RUS
 - Medical Expulsive Therapy
 - Alpha-blocker
 - NSAIDs, opioids, ?steroid?
- Clot obstruction
 - BIG 3-way
- UTI
- Trauma (including catheter)
- BPH, finasteride


PRE-ECLAMPSIA

Make an algorithm (ACOG)



More than 20 weeks
up to six weeks
postpartum

Blood Pressure
Every 15 min



MILD =
>140/90

SEVERE =
>160/>110

Symptoms (+ = possible severe)

- Headache
- Visual changes
- RUQ/epigastric pain
- Oliguria
- Edema/pulmonary edema

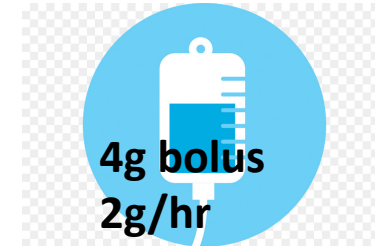
Labs/Images (abn = possible severe)

- CT SCAN? (Consider stroke)
- CBC (platelets)
- CMP (AST/ALT, Cr)
- Urine dip, Protein/Creatinine (proteinuria)

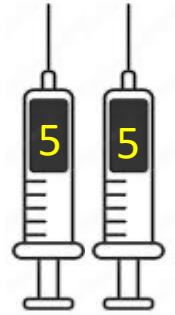
When to Consult:

- Mild-range BP: Admit vs. Follow-up
- Severe preeclampsia: Admit vs. Transfer

Severe Treatment
Magnesium sulfate



IV



IM

Antihypertensives

Nifedipine (NOT ER)

- 10 mg PO
(BP in 20 min)
- 10 mg PO
(BP in 20 min)
- 20 mg PO
(BP in 20 min)

Labetalol

- 20 IV
(BP in 10 min)
- 40 IV
(BP in 10 min)
- 80 IV
(BP in 10 min)

Transport is delayed...

Watch for Magnesium Toxicity

- Magnesium level q4h (goal = 4.9 to 8.5)
- Symptoms (depression of DTR, respiration)
- rx calcium gluconate

Monitor BPs after treatment

- q10 – 1 hour, q15 – 1 hour, q30 – 1 hour,
- q1 hour – 4 hours

ECLAMPTIC SEIZURE - make an algorithm (ACOG)

IMMEDIATELY:

Usual Seizure Care
Get the uterus off the SVC (left decub, head of bed down)
Initiate therapy

DRUGS:

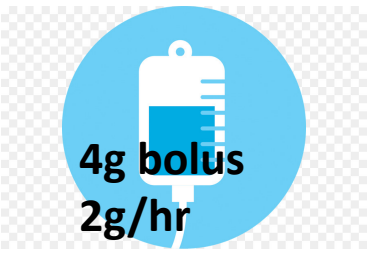
Start with magnesium first

IF SEIZURES PERSIST > 5 MIN OR RECUR:

Anti-seizure medications (diazepam, lorazepam)
Consider intubation
Consult maternal fetal medicine/neurology/critical care/anesthesia

Do We Need Emergent Delivery?
Not necessarily!

Severe Treatment Magnesium sulfate



4g bolus
2g/hr



IV

IN

Antihypertensives

| | |
|----------------------------|-------------------------|
| Nifedipine (NOT ER) | Labetalol |
| 10 mg PO (BP in 20 min) | 20 IV (BP in 20 min) |
| 10 mg PO (BP in 20 min) | 40 IV (BP in 20 min) |
| 20 mg PO (BP in 20 min) | 80 IV (BP in 20 min) |

Transport is delayed...

Watch for Magnesium Toxicity
Magnesium level q4h (goal = 4)
Symptoms (depression of DTR,
– rx calcium gluconate

Monitor BPs after treatment
q10 – 1 hour, q15 – 1 hour, q30
q1 hour – 4 hours

Eclampsia Management

- Call for assistance
 - RRT (x71200)
 - MD
 - Anesthesia
- Designate
 - Team leader
 - Checklist reader/recorder
 - Primary RN
- Ensure side rails up
- Protect airway and improve oxygenation:
 - Maternal pulse ox
 - Supplemental O2
 - Left lateral decubitus position
 - Bag-mask ventilation available
 - Suction available
- Continuous fetal monitoring
- Place IV, draw pre-eclampsia labs
- Administer mag sulfate
- Administer anti-hypertensives if appropriate
- Develop delivery plan
- Debrief patient, family, OB team

Eclampsia Medications

- 4-6g magnesium sulfate bolus → 2g/hr OR repeat 2-4g bolus if already on magnesium
- If no IV, 10g IM magnesium sulfate (5g in each buttock)
- If seizure lasts >5 minutes or recurrent seizures, consider lorazepam 2-4mg IV (may rpt x1 after 10-15min) OR diazepam 5-10mg IV Q5-10min (max 30mg)

ACOG Obstetric Emergencies in Non-Obstetric Settings

Magnesium Toxicity

Therapeutic range 5-9 mg/dL but **clinical signs** are more important for detecting toxicity (decreased/absent reflexes, altered mental status, muscle weakness, respiratory depression)

If mild toxicity suspected or serum mag >9.6mg/dL, stop infusion and recheck serum mag Q2 hours. Mag can be restarted at lower rate when serum mag <8.4mg/dL.

If risk of impending respiratory depression, administer calcium gluconate 10%, 10mL IV over 3 minutes + furosemide 20mg IV and notify anesthesia for potential intubation

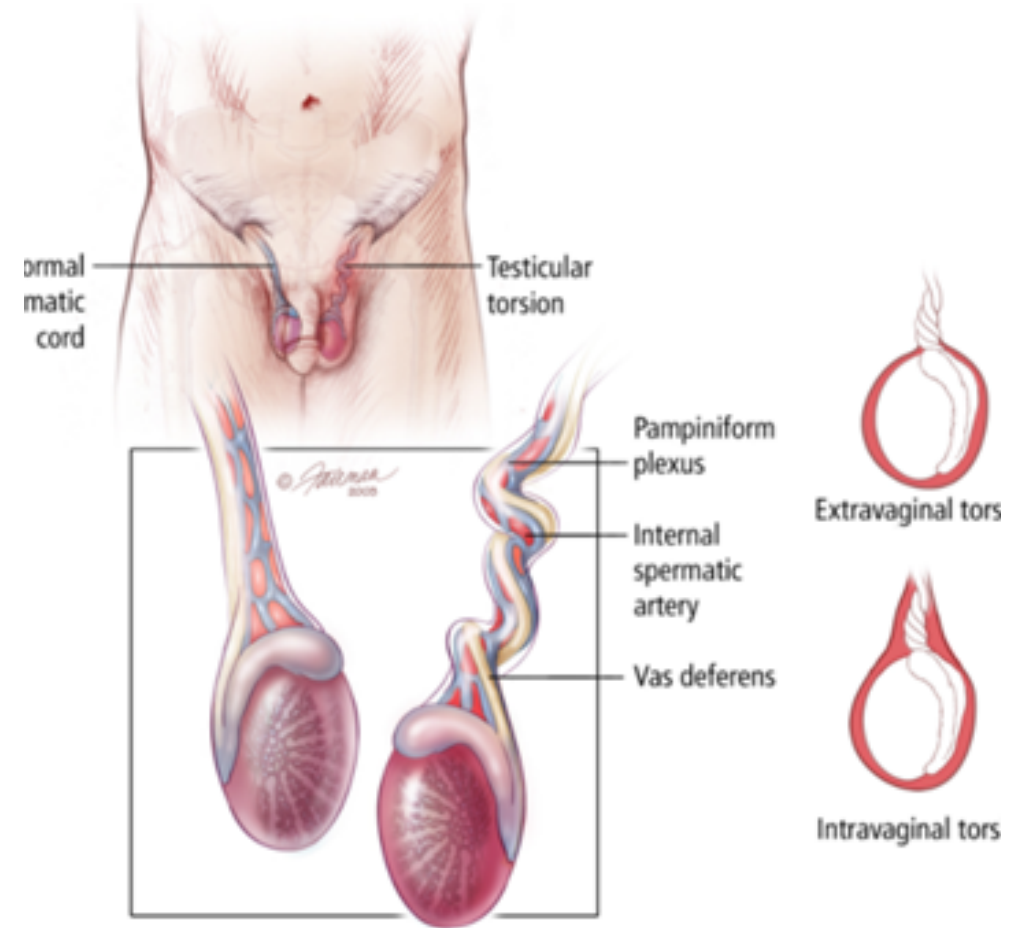
Testicular Torsion

- Flow vs none
 - US Tech vs POCUS
- Open book
- OR
- Intermittent?



Testicular Torsion

- “Acute scrotum”
 - Torsion: acute/quick; sleep/video games
 - Presentation 15%¹-38%²
 - Incidence 3.8/100k³
 - Epididymo-orchitis: gradual (?)
- Risk up: history of undescended testis or inguinal surgery
- **Clinical diagnosis** 🙋
 - Normal cremasteric reflex *strongly associated* with intact blood flow
 - Absent cremasteric reflex *associated* with torsion
 - Ipsilateral scrotal elevation



Testicular Workup for Ischemia and Torsion

- TWIST 2013⁴ (15%)
 - 0: no follow-up
 - 2-5: u/s
 - 6-7: OR 🙋
- J Urol 2016⁵ (34%)
 - 0: Nothing
 - 1-5: u/s
 - 6-7: OR 🙋
- Urol Ann 2018⁶ (38%)
 - 0-2: 50%; 5-7 24%
 - NPV 0-2 96%
 - PPV 5-7 93%
- Int Urol Nephrol 2021⁷ (50%)
 - 0-2: nothing
 - 3-5: 90% PPV
 - 6-7: 100% PPV

| TWIST PARAMETER | SCORE IF PRESENT |
|---------------------------|------------------|
| Testicular swelling | 2 |
| Hard testicle | 2 |
| High-riding testis | 1 |
| Absent cremasteric reflex | 1 |
| Nausea or vomiting | 1 |
| Total score | _ / 7 |

TWIST—Testicular Workup for Ischemia and Suspected Torsion.
Data from Barbosa et al¹³ and Sheth et al.¹⁴



⁴J Urol. 2013 May;189(5):1859-64. PMID: 23103800.

⁵J Urol. 2016 Jun;195(6):1870-6. PMID: 26835833.

⁶Urol Ann. 2018 Jan-Mar;10(1):20-23. PMID: 29416270.

⁷Int Urol Nephrol. 2021 Jan;53(1):7-11. PMID: 32844355.

**Diagnosing with a TWIST: Systematic Review and
Meta-Analysis of a Testicular Torsion Risk Score**

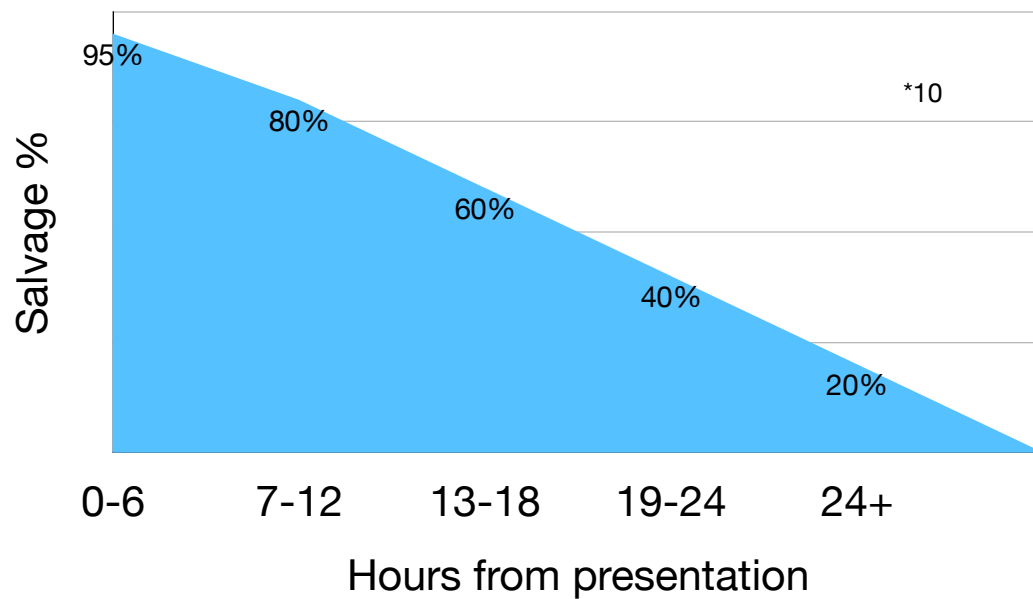
Kirby R. Qin ^{1,2,3*†} and Liang G. Qu ^{1,3*}

July 2022⁸

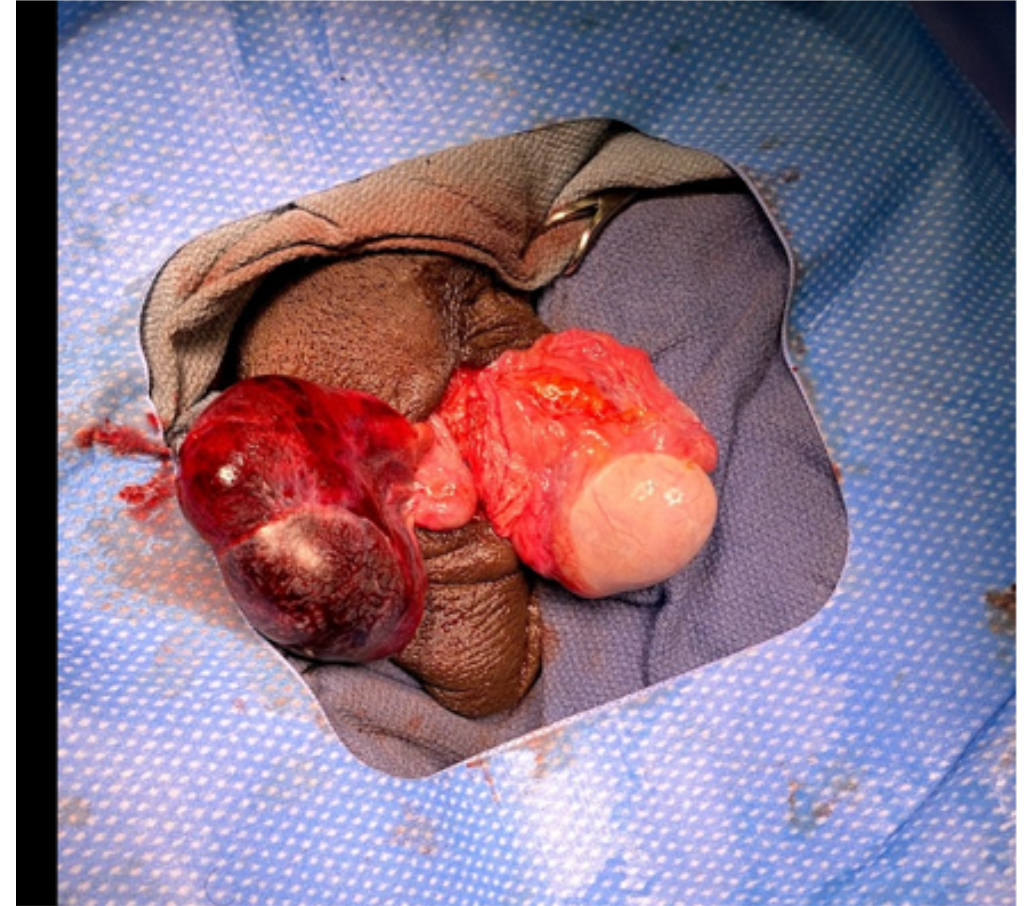“Perfect” sensitivity could not be achieved in the low-risk group as there were 17 cases of TT among 785 presentations. This raises medicolegal concerns regarding the potential for missed torsion. Orchiectomy secondary to misdiagnosed torsion is an active area for litigation and one of the most common malpractice suits among young males.³² It is unlikely that any single test or clinician can achieve 100% sensitivity, as exceptional cases are unavoidable. There were 2 cases of TT with scores of 0,^{20,23} suggesting an absence of physical signs

Predictors of Salvage

- Time “<4h”
 - 6h 100%, 6-12h 50%¹



- Use of TWIST **and** Doppler u/s⁹
 - Increased finding 18-53%



¹Scand J Surg. 2007;96(1):62-6. PMID: 17461315.

⁹J Pediatr Urol. 2023 Aug;19(4):474-476. PMID: 37080795.

¹⁰BJU Int. 2003 Aug;92(3):200-3. PMID: 12887467

OVARIAN TORSION

History

Risks: known adnexal mass, pregnancy, premenopausal

Pelvic pain (90%) – presentation varies

- Colicky → persistent
- Sudden, acute, severe pain
- Sometimes dull, sometimes sharp
- Often radiating – flank, back, groin

Nausea, sometimes vomiting (47-70%)

Fever (2-20%)

Physical Exam

Tender (absent in as many as 1/3 patients)

Low-grade fever (sometimes)

Laboratory findings

Mild leukocytosis (sometimes)

Imaging

Ultrasound

CT scan (esp if other etiologies are on ddx) vs. MRI

Postmenopausal patients

Continuous dull pain more common vs. acute-onset sharp pain

Pediatric Patients

Most frequent sign: sudden onset abdominal pain (97.5%) with nausea (67%) and/or vomiting (62%)

– mostly lower abdomen

Abd tenderness (88.4%)

Palpable mass (24%)

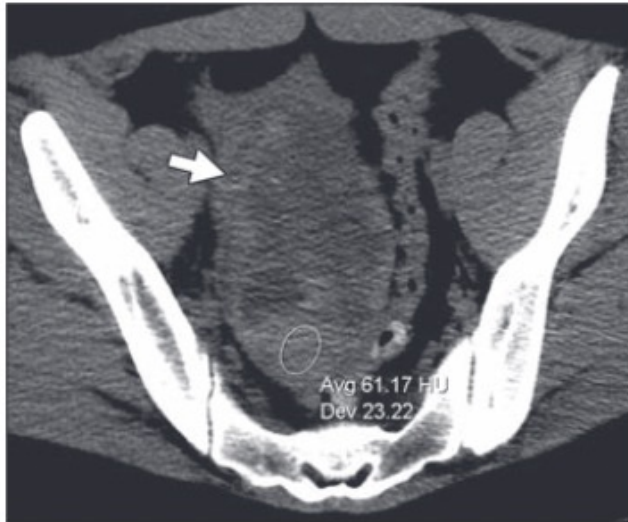
Imaging variability sensitive for ovarian torsion

- Abdominal ultrasound 79%
- CT scan 42%

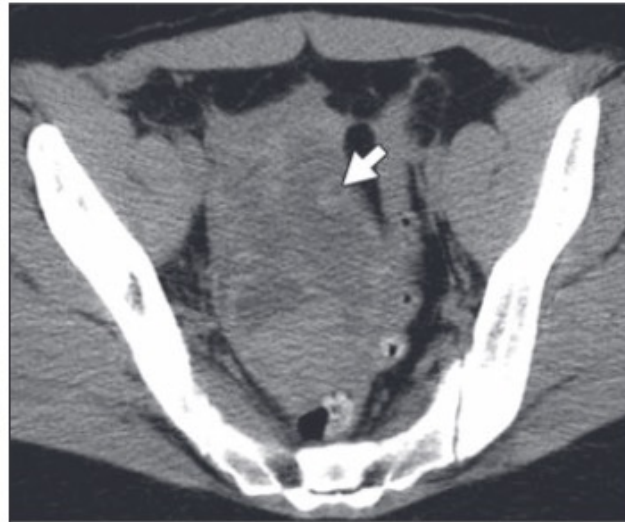Premenarchal patients – less likely to have adnexal mass, more like on US to have asymmetric ovaries and loss of Doppler flow.

Ovarian Torsion

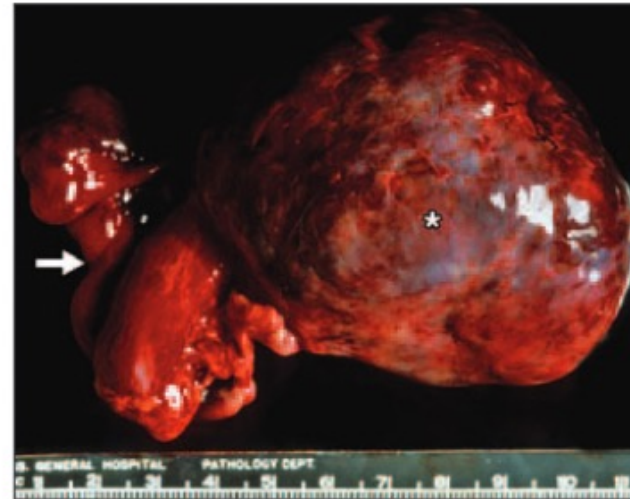
- CT SCAN and MRI
 - Enlarged ovary (most common finding, > 4 cm)
 - Twisted pedicle (seen best with IV contrast)
 - Deviation of uterus to side
 - Fallopian tube thickening



A



B



C

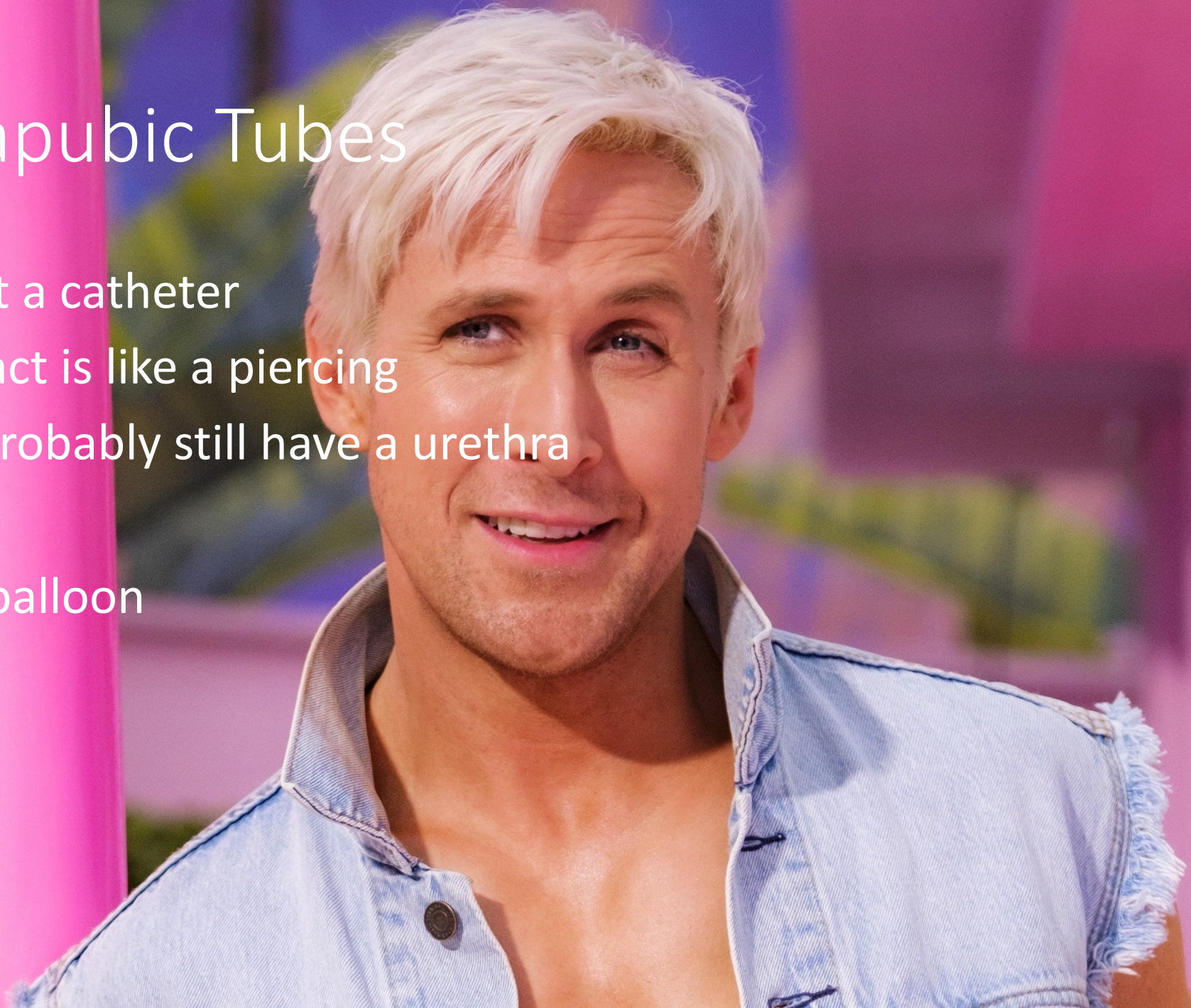Fig. 9—31-year-old woman with hematoma in torsed right ovary.

A and **B**, CT without IV contrast agent shows 9-cm right ovary containing high-density material consistent with blood (*circle, A*). Note peripheral location of follicles (*arrow, A and B*) with central afollicular stroma. Twisted pedicle was not identified.

C, Gross pathologic examination shows hemorrhage within enlarged ovary (*asterisk*) and twisted fallopian tube (*arrow*).

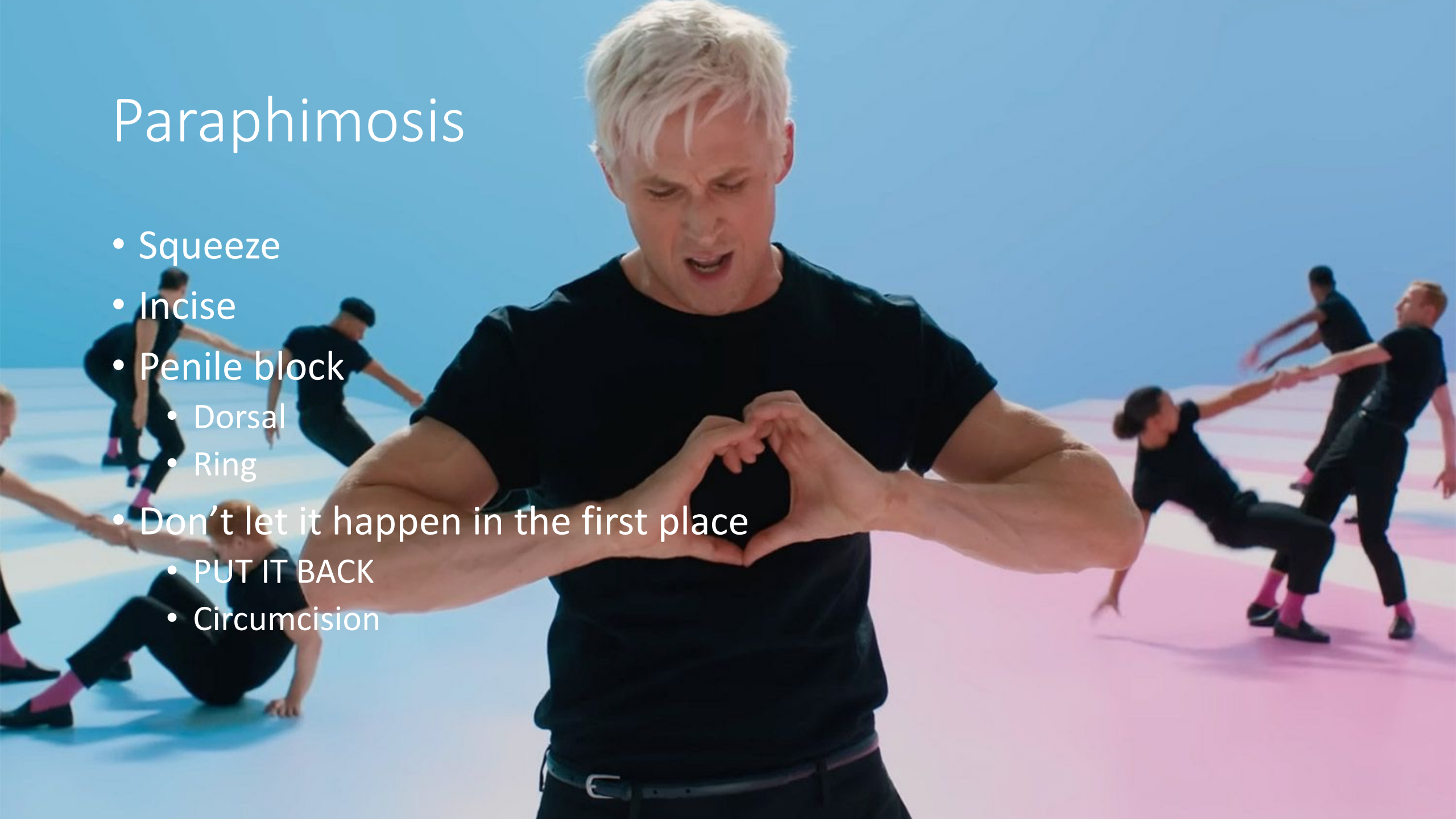Suprapubic Tubes

- It's just a catheter
- The tract is like a piercing
- They probably still have a urethra
- Stuck balloon
- SP tap



Paraphimosis

- Squeeze
- Incise
- Penile block
 - Dorsal
 - Ring
- Don't let it happen in the first place
 - PUT IT BACK
 - Circumcision

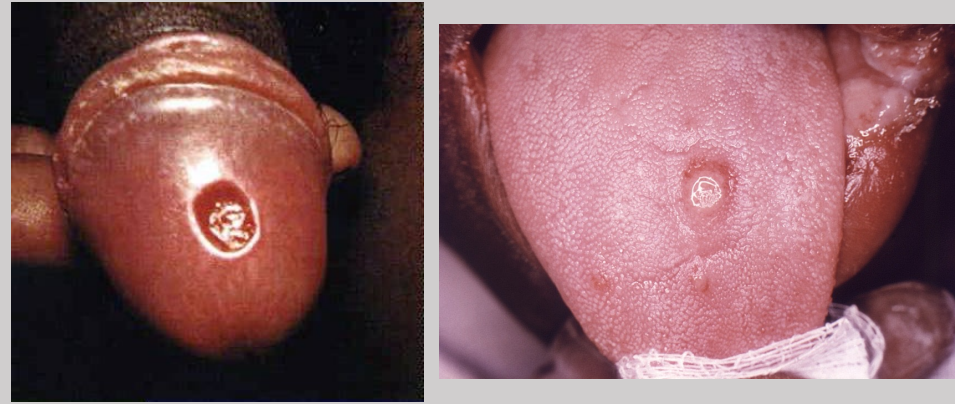


<https://www.youtube.com/shorts/4eCZe66s4H8?feature=share>

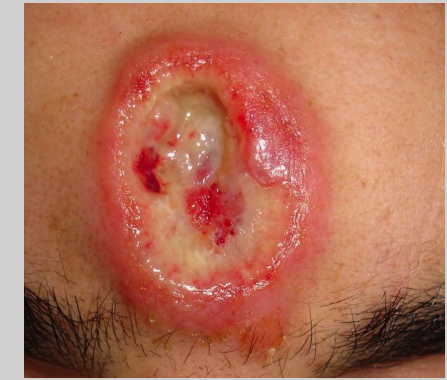SYPHILIS

Pictures courtesy of CDC

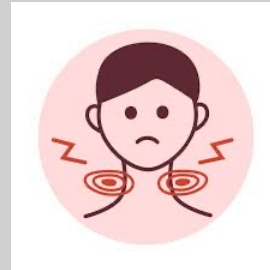
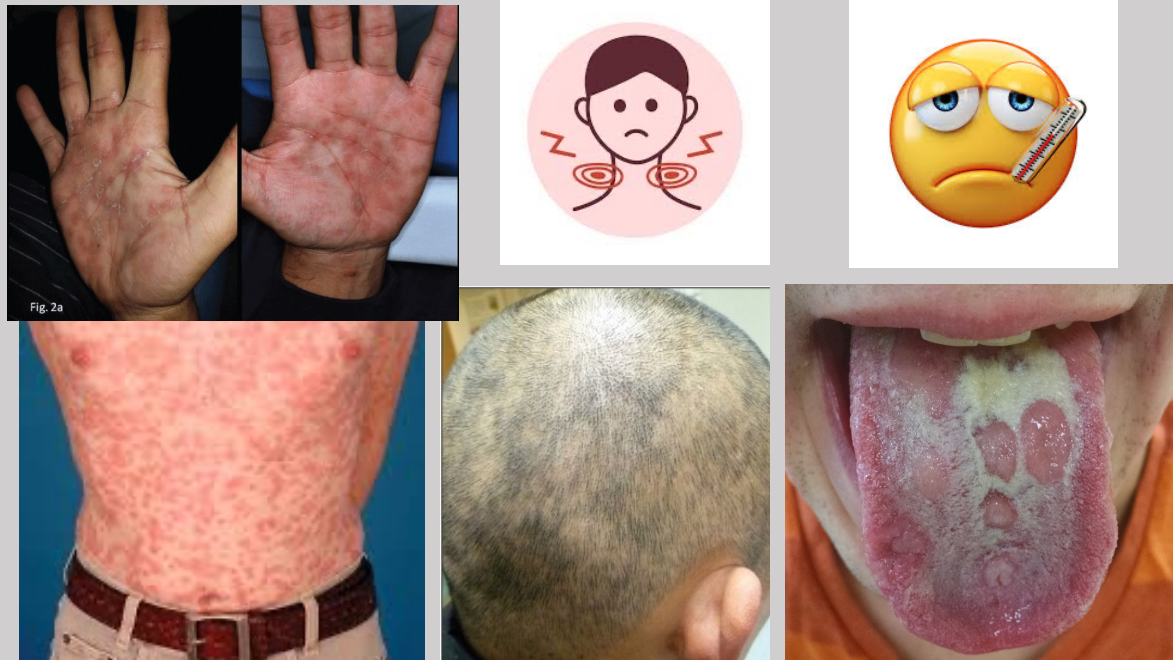PRIMARY – classic chancre is single painless BUT
Can be MULTIPLE PAINFUL lesions



TERTIARY – gummas, cardiovascular syphilis, psych manifestations, or late neurosyphilis.



SECONDARY – plantar, palmar, disseminated skin rash with flat discoloration. Look for mucocutaneous lesions, lymphadenopathy, alopecia, leukoplakia.



At Any Time – Neuro/Oculo
Microvascular – stroke-like
Tabes Dorsalis
Paresis – personality, intellectual, speech
Other: cranial nerves 7-8, gunbarrel sight, oculosyphilis

Stone + UTI

- Risk up

- Female^{1,8}
- Fever, CRP²
- Leukocytosis⁸ >15?¹
- NITR+, LE+⁷
- Pyuria >9? >150?/hpf^{1,8}
- Pregnant⁴
 - Less likely to get intervention
 - More likely to have delay to intervention
- Stone size <5 or >7?⁶

- Timing

- Delayed decompression (>2d), higher mortality³

- Treatment

- ER → OR v IR
- ER → inpatient/obs
- ER → outpatient GU
- Antibiotics? Choice?⁵

1. Shah, J Endourol 2022
2. Boeri, World J Urol 2023
3. Shah, J Urol 2020
4. Shah, Int J Urol 2023

5. Haasen, Am J Emerg Med 2019
6. Andruchow, J Urol 2021
7. Shockley, J Endourol 2018
8. Hu, PLoS One 2018

Development and validation of a risk-prediction nomogram for patients with ureteral calculi associated with urosepsis: A retrospective analysis – Hu et al, PLoS One 8/2018

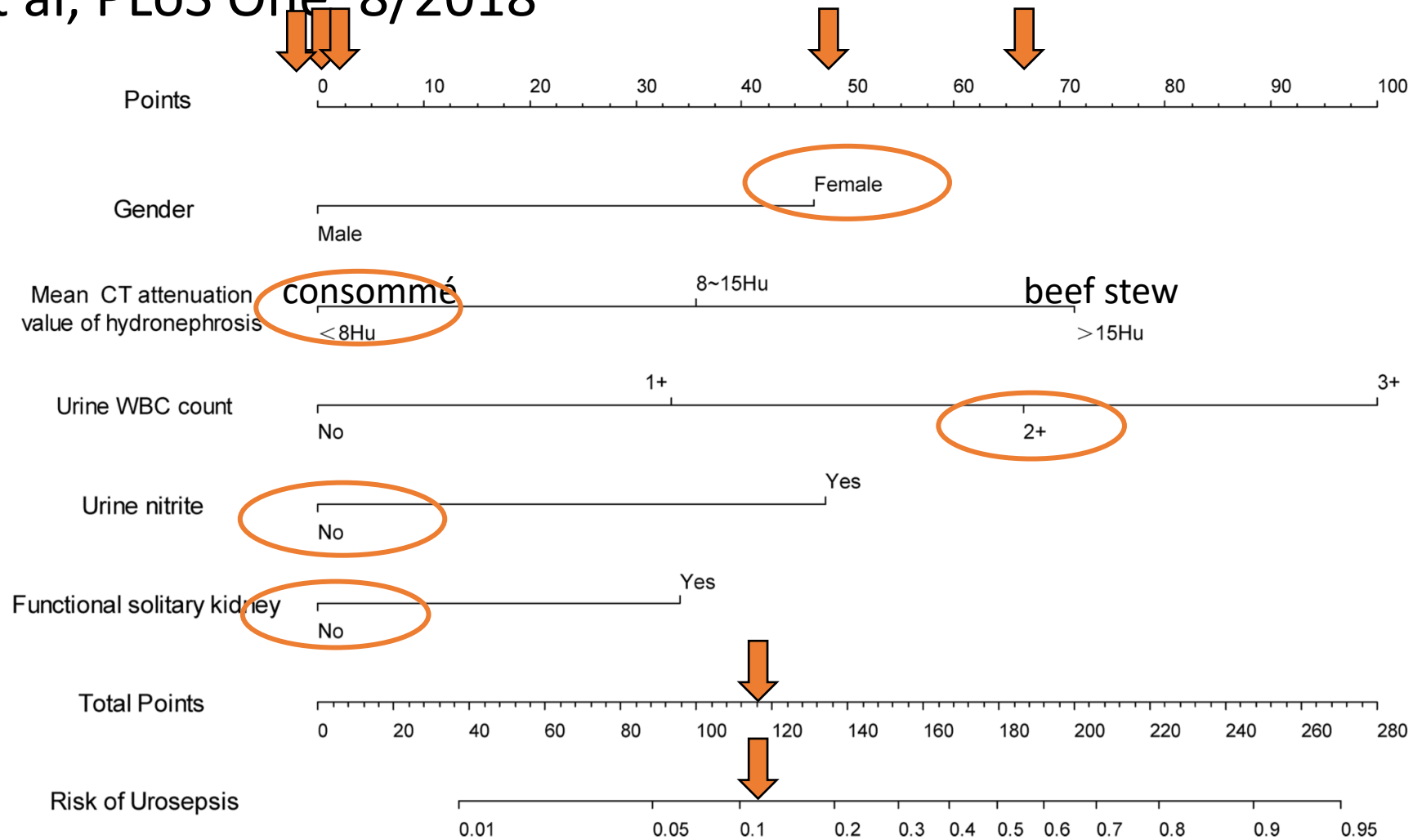


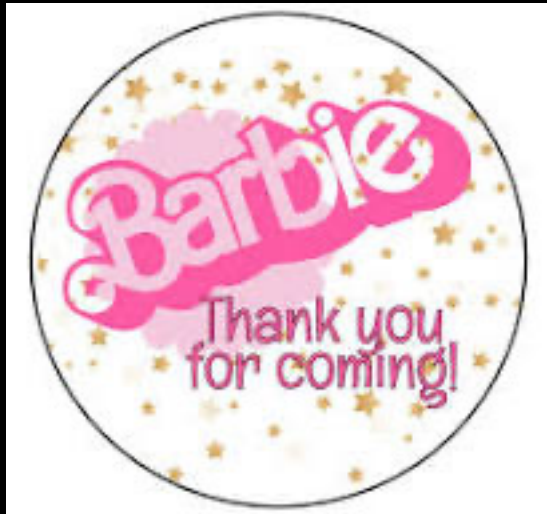Fig 1. Nomogram to predict the probability of urosepsis in the patient with ureteral calculi.

Acute Urinary Retention

- Coudé ≠ fellowship-trained Urologist (or specialty Nurse)
- Can you put in a central line?
- Stricture/meatal stenosis
 - 5Fr feeding tube
- CATH SECURE!
 - Stat-lock™ etc.
- Duration/Follow-up
- BPH meds
 - Alpha-blocker
 - Finasteride
- Anticholinergics

choovermd@gmail.com

constance.liu@ihs.gov



THE HOOVERS Friends of T.

